

VASCA Magazine

Living with Vascular Anomalies

Introduction

Vascular Anomalies

Genetics

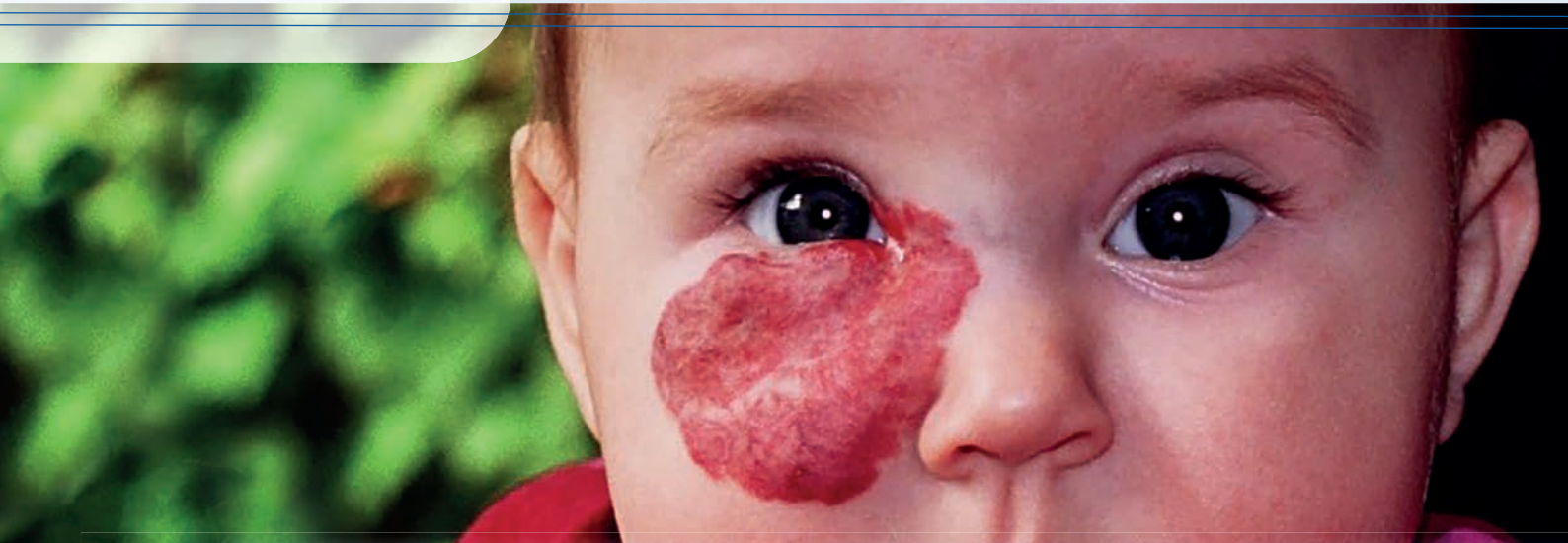Research

Treatments and Medication

Quality of Life



European
Patient
Advocacy
Group



LGD Alliance Europe
for Complex Lymphatic Anomalies



vascapa



cmtcvm



The Federal Association of
Congenital Vascular Malformations

Imprint

>> VASCA Magazine

Patient Advocates' Magazine of the VASCA-WG (VASCERN)
Edition 1 | March 2021

Digital edition (PDF) as well as print editions organised
in different countries by authorized publishers

>> Editors:

HEVAS

The Federal Association of Congenital Vascular Malformations
CMTC-OVM

LGD Alliance Europe

VASCAPA

>> Editorial office:

Caroline van den Bosch

Petra Borgards

Lex van der Heijden

Aaike van Oord

Maria Barea

>> Contact:

HEVAS, Stationsweg 6B, 3862 CG Nijkerk, Netherlands

The Federal Association of Congenital Vascular Malformations,
Blötter Weg 85, 45478 Mülheim an der Ruhr, Germany

CMTC-OVM, Koninksweg 1, 7064 KH, Silvolde, Netherlands

LGD Alliance Europe, c/o Crown Crescent, Peterculter,
Aberdeen, United Kingdom

VASCAPA a.s.b.l., Avenue Leo Errera 8, 1180 Uccle, Belgium

>> Concept & Layout:

Kathrin Sachse | KS kreativ & sozial (Germany)

○ www.creative-and-social.eu

>> Editorial's note:

The copyright in all articles published in VASCA Magazine
is reserved and may not be reproduced without permission.

Neither the publishers nor the editors necessarily agree with
the views expressed in the magazine.

This magazine and all its content is intended for information
purposes only. It is not intended for medical purposes and it
should never replace a medical advice. In case of any ques-
tion or doubt, please contact your treating doctor or spe-
cialist.

W Connected, even the
weak become powerful.

Friedrich Schiller



HEVAS
(Netherlands)

○ caroline@delaforet.nl
○ www.hevas.eu



Caroline van den Bosch



The Federal Association of Con-
genital Vascular Malformations
(Germany)

○ borgards@angiodysplasie.de
○ www.angiodysplasie.de



Petra Borgards



CMTC-OVM
(Netherlands)

○ president@cmtc.de
○ www.cmtc.nl



Lex van der Heijden



LGD Alliance Europe
(Netherlands)

○ aaike@lgda.eu
○ www.lgda.eu



Aaike van Oord



VASCAPA
(Belgium)

○ president@vascapa.org
○ www.vascapa.org



Maria Barea

Table of Contents

INTRODUCTION

CMTC-OVM
Self-Presentation of Patient Organisation..... 4

HEVAS
Self-Presentation of Patient Organisation..... 5

Federal Association of Congenital Vascular Malformations e.V.
Self-Presentation of Patient Organisation..... 6

LGD Alliance Europe
Self-Presentation of Patient Organisation..... 7

VASCAPA
Self-Presentation of Patient Organisation..... 8

Spotlight
The five patient representatives respond..... 9

The European Reference Networks (ERNs)
Prof. G. Jondeau, M. Hurard, N. Barr, K. Daoud, I. Donmez..... 11

VASCERN
Prof. G. Jondeau, M. Hurard, N. Barr, K. Daoud, I. Donmez..... 12

The VASCA WG
Prof. G. Jondeau, M. Hurard, N. Barr, K. Daoud, I. Donmez..... 14

VASCERN App
Prof. G. Jondeau, M. Hurard, N. Barr, K. Daoud, I. Donmez..... 15

The CPMS (Clinical Patient Management System)
Prof. Leo J. Schultze Kool, MD, PhD, EBIR, Ibrahim Donmez and Caroline T. van den Bosch MSc..... 16

Registries for Rare diseases
Prof. Leo J. Schultze Kool, MD, PhD, EBIR..... 18

'Patient Journeys': improving care by patient involvement
Lay description of the article in Eur. J. Hum. Genet. 2019..... 20

'Patient Journey' CMTC
Lex van der Heijden (CMTC-OVM)..... 21

VASCULAR ANOMALIES

About ISSVA
Prof. Leo J. Schultze Kool, MD, PhD, EBIR and C. van den Bosch MSc... 22

Comment on 'Cutaneous Infantile Haemangiomas with Intracranial and Intraspinal Involvement'
A. Diociaiuti et al. Acta Derm Venereol. 2020..... 24

Infantile haemangioma
C. Léauté-Labrèze, J. I. Harper, P. H. Hoeger* (Lancet, 2017)..... 25

PROS syndrome
D. Maroeska W.M. te Loo, MD and PhD..... 26

CCM and AVM - Similar and yet quite different
Priv.-Doz. Dr. med. P. Dammann..... 28

TESTIMONIAL Epilepsy due to multiple cerebral cavernomas
Anja R. (Fed. Ass. of Congenital Vascular Malformations)..... 31

TESTIMONIAL Facial Infiltrating Lipomatosis (FIL)
Brenda Kluijver (HEVAS)..... 32

TESTIMONIAL Microcystic lymphatic malformation
Brenda Kluijver (HEVAS)..... 33

TESTIMONIAL Chloe's story (CMTC)
Sarah Gross (CMTC-OVM) 34

TESTIMONIAL Klippel Trenaunay Syndrome (KTS)
Brenda Kluijver (HEVAS)..... 36

TESTIMONIAL Julia (9) has a hemangioma on her face
Brenda Kluijver (HEVAS)..... 37

GENETICS

Clear and simple explanations of genetics of vascular malformations
D. Maroeska W.M. te Loo, MD, PhD..... 38

TESTIMONIAL Genetics
Astrid (VASCAPA)..... 39

RESEARCH

Importance of Scientific Research for Vascular Anomalies
Interview with Prof. Miikka Vikkula by Maria Barea (VASCAPA)..... 40

V.A. Cure Project
Project Consortium & Mina Todorovic..... 44

TREATMENTS AND MEDICATION

Treatment of Vascular Anomalies at Multidisciplinary Centers
Interview with Prof. Laurence Boon by Maria Barea (VASCAPA)..... 47

TESTIMONIAL Being treated at a multidisciplinary center
Juan & Maria (VASCAPA)..... 50

Future Options in the Treatment of Vascular Malformations
Dr. Friedrich Kapp, MD 51

TESTIMONIAL Sirolimus treatment since birth
Shanti (VASCAPA)..... 54

TESTIMONIAL Implementation of Sirolimus (VASE study)
Tamara & Franck (VASCAPA)..... 55

Intranodal Lymphatic Imaging and Treatment
Willemijn M. Klein, MD, PhD..... 56

Transversal Working Group on 'Pregnancy & Family Planning'
Petra Borgards (Fed. Ass. of Congenital Vascular Malformations)..... 58

Treatment of vascular anomalies with Surgery, Embolisations, Sclerotherapy and Laser
Nader Ghaffarpour, MD, PhD, Caroline T. van den Bosch MSc..... 59


QUALITY OF LIFE

Experiences of patients and relatives in diagnosis, treatment and living with vascular malformations
Maria Bäumer (Fed. Ass. of Congenital Vascular Malformation)..... 62

The OVAMA project
Max M. Lokhorst, MD (PhD candidate)..... 64

TESTIMONIAL Living with narrow escapes
Aaike, Hajni & Max (LGD Alliance Europe)..... 66

After diagnosis
Johannes Verheijden (CMTC-OVM)..... 68



Glossary 72

List of VASCA-WG Healthcare Providers..... 74

List of Authors 75

CMTC-OVM (Cutis Marmorata Telangiectatica Congenita and Other Vascular Malformations)

Self-Presentation of Patient Organisation



Disease profiles:

Both identified as well as unidentified vascular malformations.

Country:

CMTC-OVM is based in the Netherlands and is a worldwide non-profit patient organisation (supporting families from around the globe).

Foundation year: 1997

Languages spoken: Dutch, English and German.

Languages website and material:

The website is available in native Dutch and native English and can be translated with a mouse click to over 100 languages. The information material is available in at least Dutch, English, French, German and Spanish.

Main goals:

To improve the quality of life of people suffering from vascular abnormalities (blood vessel abnormalities), such as CMTC ('Van Lohuizen syndrome'), and stimulate scientific research into these disorders.

Core activities:

1. Information via website (incl. pedia and knowledge base), social media, brochures, booklets and newsletter (in multiple languages).
2. International physical and online conferences.
3. Online secure community.
4. International webinars.
5. International family days.
6. Genetic research.
7. Personal medical, psychological and psychosocial support.
8. Patient advocates in multiple countries for local support.
9. Collaboration with international umbrella organisations such as EURORDIS, CORD, Genetic Alliance, Global Skin, IAPO, ICord, NORD and rare disease organisations in multiple countries.

Chairperson & Contact person VASCA:

Lex van der Heijden
 ○ president@cmtc.nl

Website:

○ www.cmtc.nl/en

Social media:

○ www.cmtc.nl/en/members/be-informed/social-media-channels/



Generated with www.qrcode-monkey.com

Photo: Lex van der Heijden



Some of our members

HEVAS



Disease profiles:

All types of vascular malformations, vascular tumours, syndromes and PROS.

Country: Netherlands

Foundation year: 2007

Language(s):

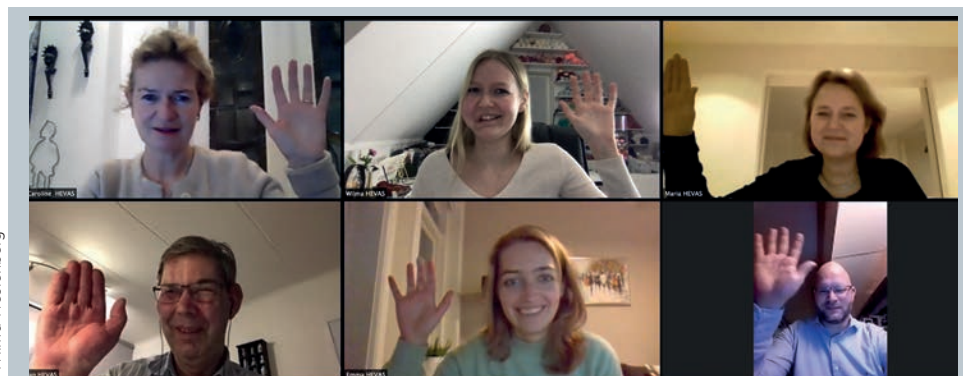Dutch (also English and German for communication)

Mission:

HEVAS provides support and education for patients and families affected by vascular anomalies. There is a strong focus on the correct diagnosis from centres of expertise, the best treatment options/research trials and quality of life for our patient groups. HEVAS encourages clinical research on vascular anomalies and overgrowth syndromes.

Core activities:

- Interacting with and educating our patient community via website and social media channels/groups.
- Publication of a quarterly magazine and production of brochures and videos about the disorders.
- Organizes yearly face-to-face and additional online meetings for its members.



Hevas board members

Photo: Wilma Westenber

Self-Presentation of Patient Organisation

- Organizes conferences for doctors to raise awareness of the disorders.
- Collaborates with the Dutch Centres of Expertise in a national network and is actively involved in guidelines on the disorders.
- Member of The Dutch Patient Alliance for Rare and Genetic Diseases (VSOP).
- Active in the European Reference Network VASCERN and works with Eurordis.
- Attends medical conferences such as ISSVA-meetings.

Chairperson:

Maria Jongma
 ○ info@hevas.eu

Contact person VASCA:

Caroline van den Bosch
 ○ caroline@delaforet.nl

Social media:

Facebook@hevas.nl
 ○ www.facebook.com/Hevas.nl
 YouTube: Patient Organisation Hevas
 ○ www.hevas.eu/youtube
 Instagram@patientenvereniginghevas
 ○ www.instagram.com/patientenvereniginghevas/
 Twitter@HevasNederland
 ○ www.twitter.com/HevasNederland


Website:

○ www.hevas.eu



Federal Association of Congenital Vascular Malformations e.V.

Self-Presentation of Patient Organisation



Disease profiles:

All types of vascular malformations including cerebral cavernous malformations and syndromes.

Country: Germany

Foundation year: 2006


Language(s): German
(also English for communication)

Main goals:

Improvement of diagnosis, treatment and quality of life of patients and caregivers through information, exchange of experiences, support for research, networking and public relations work.

Core activities:

Operation of a website and social media channels (Facebook and Youtube); Newsletter for members, provision of a platform for information and exchange of experiences (via Zoom and Slack for members), publication of a regular professional journal ('Das Magazin'), organisation of biennial Face2Face meetings of members and physicians, participation in the German Interdisciplinary Society for Vascular Anomalies (DIGGEFA) and in umbrella organisations (ACHSE and EURORDIS and European Reference Network VASCERN), integration of the 'Information Portal for Cerebral Cavernomas' and, last but not least, contact points for affected persons and caregivers.



Some of the active members (Left foreground: René Strobach)

Photo: K. Sachse

Chairperson:

René Strobach
 ○ strobach@angiodyplasie.de

Contact person VASCA:

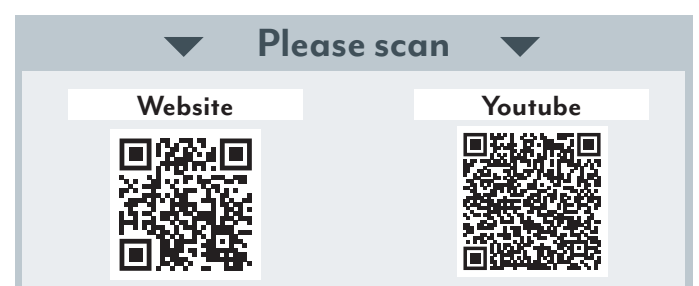
Petra Borgards
 ○ borgards@angiodyplasie.de

Website:

○ www.angiodyplasie.de

Social media:

○ www.facebook.com/angiodyplasie
 ○ www.youtube.com/results?search_query=bundesverband+angeborene+gef%C3%A4%C3%9Ffehlbildung+en+e.v
 ○ www.kavernom.de



Generated with www.qrcode-monkey.com

LGD Alliance Europe



Disease profiles:

All types of complex lymphatic anomalies (CLAs), including Gorham's Disease (GSD), Kaposiform Lymphangiomatosis (KLA), General Lymphatic Anomaly (GLA) and Central Conducting Lymphatic Anomaly (CCLA).

Country: Europe

Foundation year: 2010

Language(s):

English, Dutch, Spanish, Italian and several other European languages.

Main goals:

Provide support, education and hope to patients and families affected by CLAs. That is our mission. Just as important is to promote basic and clinical research on the cause of Lymphangiomatosis and Gorham's Disease and support the development of effective diagnosis, identifying the effective treatment and ultimately a cure for these diseases.



Patients and volunteers accompanied by Prof. Dr. Jochen Rößler at the first patient meeting in november 2016.

Photo: Hajni Zsolcai - Facetphoto

Self-Presentation of Patient Organisation

Core activities:

In order to realise its goals, the LGD Alliance Europe does the following:

- Raise general public awareness and distributes comprehensive information on CLAs.
- Offer support and hope for patients and families by enabling to make contact with others.
- Assist patients and their family members by providing general information on these diseases and contacts to the doctors and clinical centres with experience treating these patients.
- Promote research to achieve a more active approach towards developing and executing a research strategy and program for the study of CLAs.
- Work with umbrella organisations for rare diseases, The VASCERN and other rare disease health organisations to advocate for rare disease policies and research funding collaboration.
- Many of the activities are planned and executed in co-operation with the LGD Alliance in the United States:

○ www.lgdalliance.org

President & Contact person VASCA:

Aaike van Oord
○ aaieke@lgda.eu


Website:

○ www.lgda.eu

Social media:

- www.facebook.com/LGDAllianceEurope
- www.twitter.com/igda_eu
- www.youtube.com/channel/UCmWRbcbmhE5T_I18dZdwdbQ/videos

Generated with www.qrcode-monkey.com



VASCAPA (VASCular Anomaly Patient Association)

Self-Presentation of Patient Organisation



Disease profiles:

All types of vascular anomalies including syndromes.

Country: Belgium

Foundation year: 2012

Language(s): French and Dutch
(also possible: English, German, Italian, Arabic and Spanish)

Mission:

We at VASCAPA believe in a good quality of life for people affected by vascular anomalies and their families. VASCAPA is a patient association that aims to help, support and inform people affected by vascular anomalies and their families, while supporting research.

Core activities:

Our actions are aimed at:

- Informing patients and relatives via our website, social media and newsletter.
- Guiding people affected towards the most appropriate medical care.
- Supporting patients and their relatives, promote exchange of experiences via patient gatherings, and in patient-doctors meetings.
- Support research and participate in working groups on rare diseases,
- Partnering with Belgian and European patient organisations (RaDiOrg, LUSS, VPP, EURORDIS and VASCERN) to raise awareness of vascular anomalies and rare diseases in general among the public, policy makers and health professionals, and to elevate the patient's voice.



Some of the active members

Photo: VASCAPA

President & Contact person VASCA:

Maria Barea

○ president@vascapa.org

Website:

○ www.vascapa.org

Social media:

Facebook@VASCAPA.asbl

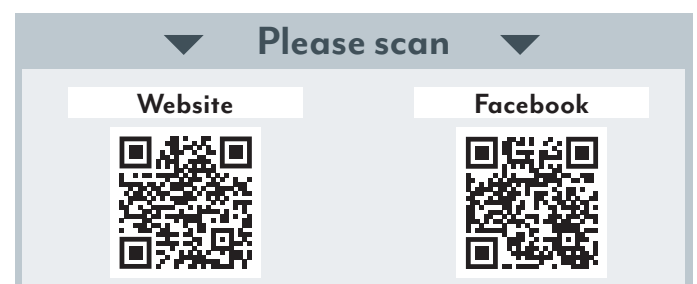○ www.facebook.com/VASCAPA.asbl/

Instagram@vascapa_asbl

○ www.instagram.com/vascapa_asbl/

Twitter@VASCAPA

○ www.twitter.com/VASCAPA



Generated with www.qrcode-monkey.com



The five patient representatives respond to questions about their work, their personal motivations and their wishes and hopes for the 'ERN' project

Aaike van Oord, Caroline van den Bosch, Lex van der Heijden,
Maria Barea and Petra Borgards

Can you tell us something about the reasons for your commitment?

Aaike: 'The LGD Alliance Europe is representing patients with rare complex lymphatic malformations or CLAs. My son Bo had complex and multifocal lymphatic anomalies, which gave him reoccurring problems with chylus around the lungs and often pains in his back and head. Unfortunately, Bo passed away in May 2020 due to a pneumococcus bacterial infection, two weeks after his eighth birthday. To everybody's surprise his immune system could not withstand this 'rather simple' bacteria to spread to vital parts of the body.'

Caroline: 'My son (born in 2000) had an extreme haemangioma on his chest, upper arm and shoulder which led to complications such as severe infections and bleedings, growth imbalance and cardiac failure. There was no patient organisation in the Netherlands where I could find information at that time, so I reached out to patient organisations on vascular anomalies in the USA, attended medical conferences and read medical articles to educate myself. When the worst was over I could dedicate myself to HEVAS so that, together with the other founders, we could help other parents and patients with all types of vascular malformations including syndromes, PROS and vascular tumours. Misdiagnoses of vascular anomalies are still common and we refer patients to the right doctors in the Netherlands and abroad.'

Lex: 'In 1993 our daughter was born with the CMTC skin/vascular malformation which was in fact my trigger to start the global CMTC-OVM organisation in 1997. CMTC is rather often a combination of skin and vascular diseases. The com-

plications can vary a great deal, such as overgrowth of limbs, organ issues, brain issues and many more. At least six patients have died due to complications as far as we know at this stage.

On our website we have listed the possible complications in relation to the location of the markings for instance. Since 2009 we are supporting patients, their families and healthcare providers with other vascular malformations (OVM) as well.'

Maria: 'My son was born in 2007. At first, five different doctors misdiagnosed him. It was only after a thorough internet search that we learnt that he had an arteriovenous malformation (AVM) in his face, and were able to find expert medical care. But there were still many questions and fears remaining for us. Our doctor put us in contact with VASCAPA, and there was an immediate click: for our son with other young patients, and for us with other parents and adult patients. Since then, we have found a second family that fully understands, supports and helps us. We are now involved in VASCAPA as we also want to help others.'

Petra: 'My son, born in 1989, has an AVM in the upper lip and right cheek, which led to strong redness, swelling, bleeding and pain. For many years his disease was misdiagnosed with hemangioma, and unsuccessfully treated. Only in 2009 he was successfully operated by a multidisciplinary team and has been symptom-free ever since. His psychological wounds were not healed by being bullied and gawked at, and he was unable to make up for many things he missed at school and during his apprenticeship due to frequent absences. This side of the illness was not taken seriously or appreciated by the doctors, the school, the employer and society in general. This is one of the reasons why I myself became active in the Federal Association of Congenital Vascular Malformations and later in VASCA.'





Vascular Anomalies Europe Patient Organisations Meeting on May 29, 2018 in Amsterdam (some participants, from left):

Juan Lage (VASCAPA, Belgium), Jutta Holtkamp, Petra Borgards & Werner Holtkamp (Bundesverband Angeborene Gefäßfehlbildungen e.V., Germany), Dr. Linda Rozwell-Shannon (Birthmark Foundation, USA), Caroline van den Bosch (HEVAS, Netherlands), Aaike van Oord (LGD Alliance Europe, Netherlands), Maria Jongma (HEVAS, Netherlands).

Photo: Petra Borgards

How did you become involved in the VASCERN project?

Our organisations were either approached directly by individual doctors in the process of setting up the ERNs to send a representative, or through EURORDIS, or were involved in the selection process of the national centres of expertise. Most of us started at the establishment of the ERNs, and were thus able to help in their development.

How do you as an ePAG patient advocate participate in the activities of VASCERN?

We are all active in VASCA and VASCERN meetings (some with the doctors, others with the patient representatives and once or twice a year with all members), in our own national or international networks and in two transversal workings groups (Registry and Pregnancy/Family Planning).

What were your most memorable moments as an ePAG patient advocate?

Each of us has our own memorable moments. After the inspiring kick-off meeting in Vilnius in 2017, there was an event that we consider the biggest success of our work, our 'moving forward', 'growing together' and 'being recognised' so far: ISSVA 2018 in Amsterdam. We were very fortunate that the ISSVA president at that time was Professor Laurence Boon, one of our current VASCA chairs. Not only ERN was an

ISSVA conference topic, but also Caroline van den Bosch was able to present the work of the patient representatives. We had an information desk in the large hall, which was well visited and perceived with recognition for our work. Also there was a meeting of representatives of European patient organisations, opened by Laurence Boon, even attended by Dr. Linda Rozwell-Shannon of the American Vascular Birthmarks Foundation.


As a patient advocate, what is your hope for VASCERN and for the ERNs in general?

The ERNs need recognition and budget from the Member States. Besides, national networks need to be established to work together with the ERNs. Our greatest hope is that everyone realises the importance and the relevance of the ERNs.

We need Europe-wide standards for diagnosis, treatment and improvement of the quality of life of patients and their families. ERNs should become a hub for research and treatment of the diseases they represent as well as for networking among hospitals, doctors, therapists and the patients themselves.

“ In yesterday's pain lies today's strength.

Paulo Coelho



Caroline van den Bosch presents the work of the ePAGs VASCA-WG

Photo: Petra Borgards

The European Reference Networks (ERNs)

Prof. Guillaume Jondeau, Marine Hurard, Natasha Barr, Karen Daoud and Ibrahim Donmez

In order to implement the European Union's Directive 2011/24/EU on the application of patients' rights in cross-border healthcare, the European Commission (DG SANTE) launched the creation of the first 24 European Reference Networks (ERNs) for rare, low-prevalence and complex diseases in Vilnius, Lithuania on March 9th, 2017.



Figure 1: Some of VASCERN's Members at the 3rd Conference on European Reference Networks in Vilnius, Lithuania, March 2017.

Photo: initial group in Vilnius and VASCA-WG

This momentous occasion followed the call issued in 2016 and the subsequent process of evaluation (Independent Assessment Body mandated by the European Commission and ERN Board of Member States approval), which gave all 24 networks the ERN label for their first 5 years of operation and was a culmination of the policy efforts made, in particular by the patient advocacy of EURORDIS, and progress achieved by previous EU-funded rare disease projects over the last decade.

The goal of the ERNs is clear: to offer the nearly 30 million EU citizens affected by these rare diseases, the opportunity to benefit from high-quality and cost-effective care no matter where they live in Europe.

As knowledge is scarce and treatment options are limited when it comes to rare diseases, the creation of these networks is a unique opportunity to pool knowledge and data from across Europe, allowing for medical advances to be made to improve the lives of rare disease patients.

ERNs are highly specialised networks involving Healthcare Providers (HCPs) from across Europe.

They aim to tackle complex or rare medical diseases or conditions that require highly specialised treatment and a concentration of knowledge and resources.

The European Patient Advocacy Group (ePAG) and its patient advocates are at the centre of all ERNs, actively participating as key partners in order to bring the patients' perspective to the table.

Each ERN covers a specific medical field, with VASCERN being the European Reference Network on Rare Multisystemic Vascular Diseases. The challenges ahead for the ERNs, as they near the end of their first five years of operation, is to ensure proper funding for the continuation of the networks as well as their integration into the national healthcare systems. The creation of national networks, which already exist in some European countries but that are currently being discussed/ developed in others, is essential in order to ensure a harmonious connection between the ERNs and the national healthcare systems.

WHICH DISEASES ARE CURRENTLY COVERED BY THE ERNS?

Each of the 24 ERNs address a specific area of intervention, though they also often work together.

- **ERN BOND:** bone disorders
- **ERN CRANIO:** craniofacial anomalies and ear, nose and throat (ENT) disorders
- **Endo-ERN:** endocrine conditions
- **ERN EpicARE:** epilepsies
- **ERKNet:** kidney diseases
- **ERN-RND:** neurological diseases
- **ERNICA:** inherited and congenital anomalies
- **ERN LUNG:** respiratory diseases
- **ERN Skin:** skin disorders
- **ERN EURACAN:** adult cancers (solid tumours)
- **ERN EuroBloodNet:** oncological and non-oncological hematological diseases
- **ERN eUROGEN:** urogenital diseases
- **ERN EURO-NMD:** neuromuscular diseases
- **ERN EYE:** eye diseases
- **ERN GENTURIS:** genetic tumour risk syndromes
- **ERN GUARD-HEART:** diseases of the heart
- **ERN ITHACA:** congenital malformations and rare intellectual disability
- **MetabERN:** hereditary metabolic disorders
- **ERN PaedCan:** paediatric cancer
- **ERN RARE-LIVER:** hepatological diseases
- **ERN ReCONNET:** connective tissue and musculoskeletal diseases
- **ERN RITA:** immunodeficiency, autoinflammatory and autoimmune diseases
- **ERN TRANSPLANT-CHILD:** conditions and complications linked to the transplantation in children
- **VASCERN:** rare multisystemic vascular diseases

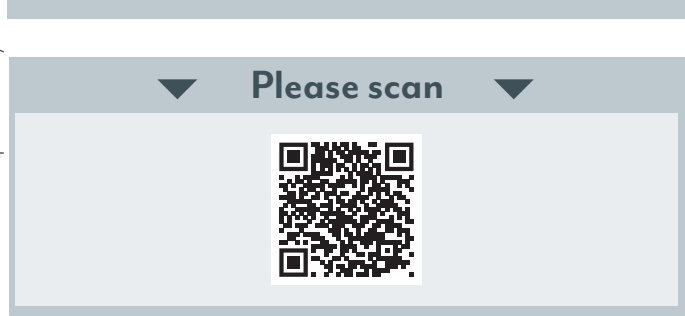


Photo: ec.europa.eu/health/sites/health/files/em/docs/2018_patientsflyer_en.pdf

Generated with www.qr-code-monkey.com

VASCERN

Prof. Guillaume Jondeau, Marine Hurard, Natasha Barr, Karen Daoud and Ibrahim Donmez

VASCERN, the European Reference Network on Rare Multisystemic Vascular Diseases, is dedicated to gathering the best expertise in Europe in order to provide accessible cross-border healthcare to the estimated 1.3 million European patients with rare vascular diseases.

These include arterial diseases (affecting aorta to small arteries), arteriovenous anomalies, venous malformations and lymphatic diseases. These rare and complex diseases, which can sometimes be associated with serious complications, require a multidisciplinary approach to patient care, which involves many different specialists belonging to the Healthcare Provider (HCP) Members' teams.

VASCERN currently gathers 31 expert teams from 26 highly specialised multidisciplinary HCPs, plus 7 Affiliated Partner Centers, from 16 EU Member States, in this area of expertise. It also includes more than 65 European Patient Organisations, members of the European Patient Advocacy Group (ePAG).

Through our 5 Rare Disease Working Groups (RDWGs), as well as several Thematic Working Groups and the ePAG, we aim to improve care, promote best practices and guidelines, reinforce research, empower patients, provide training for healthcare professionals and realise the full potential of European cooperation for specialised healthcare by exploiting the latest innovations in medical science and health technologies.

VASCERN, coordinated by a dedicated EU co-funded project-team at Bichat Hospital (Assistance Publique-Hôpitaux de Paris) and led by **Professor Guillaume JONDEAU**, signed a 5 year Framework Partnership Agreement (FPA) with the European Commission to receive EU co-funding to support VASCERN's coordination and networking activities.

Under this FPA, VASCERN signed a Specific Grant Agreement (SGA) for its third to fifth year of official activities, which runs until February, 28th, 2022. VASCERN also receives other EU co-funding from the EU 3rd Health Programme for its registries (grant from May 2020 to May 2023) and from the Connecting Europe Facility Telecom eHealth for ERNs for its eHealth and eLearning activities, in particular for the management of the Clinical Patient Management System (CPMS).

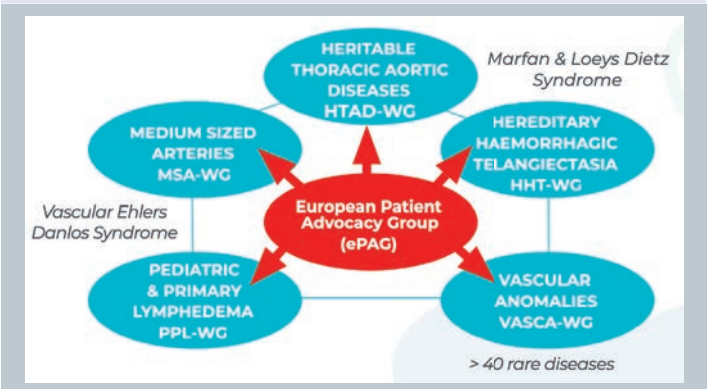
'VASCERN has connected expert centres from different countries more closely by creating regular discussions (even during

the COVID period), which include the patients, with the aim of providing guidelines, gathering larger patient groups to gain more expertise, proposing a standard scheme for the diagnosis, therapy and follow-up of these rare vascular diseases, and proposing expert advice on difficult cases', states Professor Guillaume Jondeau.

'The ERNs highlight the value of cross-border partnerships and patient-clinician collaboration when it comes to improving rare disease management and care.'

The Rare Disease Working Groups (RDWG) of VASCERN:

- Hereditary Haemorrhagic Telangiectasia (HHT-WG),
- Heritable Thoracic Aortic Diseases (HTAD-WG),
- Medium Sized Arteries (MSA-WG),
- Pediatric and Primary Lymphedema (PPL-WG) and
- Vascular Anomalies (VASCA-WG).



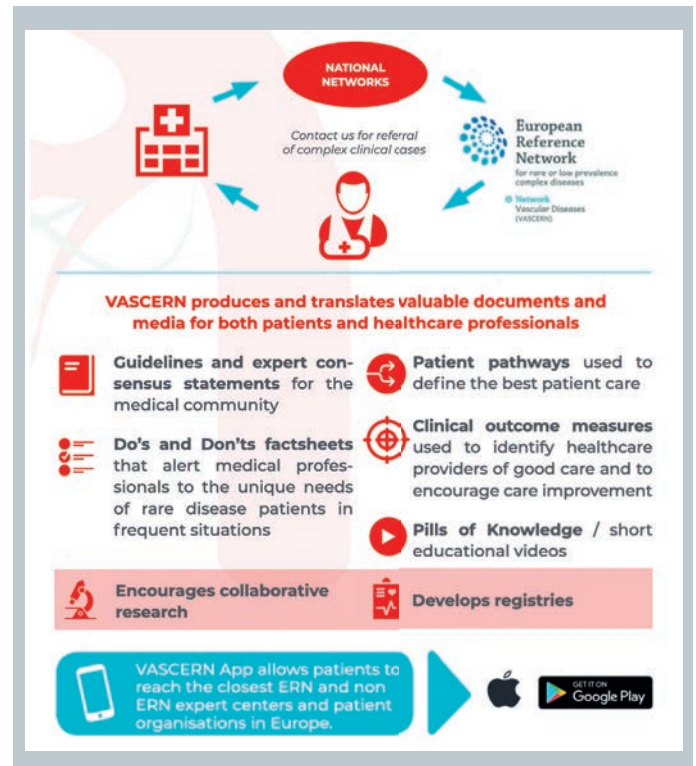
Patient advocates are involved in all activities of VASCERN via a designated ePAG Co-Chair in each RDWG that liaises with the ePAG.

VASCERN's activities aim to realise the three objectives which were chosen by our European Reference Network on rare diseases, based on the legal basis (Directive 2011/24/EU on the application of patients' rights in cross-border healthcare), namely:

- 1) Realise the potential of European cooperation** regarding highly specialised healthcare for patients and for healthcare systems by exploiting innovations in medical science and health technologies.
- 2) Reinforce research, epidemiological surveillance like registries and provide training** for healthcare professionals.
- 3) Encourage the development of quality and safety benchmarks** and help develop and spread best practice within and outside the European Reference Network.

We achieve these objectives through our 15 work packages, which are the following:

- WP1 Coordination/ Project Management
- WP2 Dissemination/ Communication
- WP3 Evaluation of the Action Implementation
- WP4 Sharing of Experience: Discussion of Complex Clinical Cases
- WP5 Patient Pathways: Improvements and Updates
- WP6 Mobile Application
- WP7 Pills of Knowledge
- WP8 Registries
- WP9 Clinical Trials & Research
- WP10 Availability of Videos on YouTube
- WP11 Multidisciplinary School for Multisystemic Vascular Diseases (Year 5)
- WP12 Definition of Clinical Outcomes
- WP13 Writing Clinical Practice Guidelines
- WP14 Dos and Don'ts Factsheets
- WP15 VASCERN Clinic Days (Year 5)



Finally, VASCERN uses the tools provided by the European Commission (WebEx for videoconferences, the ERN Collaborative Platform for internal communication, and the CPMS for the discussion of complex clinical cases) in order to progress on our work packages. In order to communicate and disseminate information about our network and its valuable outputs in various EU languages, VASCERN uses its website and social media pages (Twitter, Facebook, YouTube, and LinkedIn).

We encourage you to learn more about VASCERN by visiting our website and subscribing to our social media channels.

The best guarantee for the future of our network is the friendships and the enthusiasm that we have been able to create, which drives our members to continue to work hard together in an efficient manner.

All information about the VASCA content described here, the VASCA WGs, patient panels, and videos can be found via the following website:
<https://vascern.eu>




Photo: LGD Alliance - Fotolia 91764451

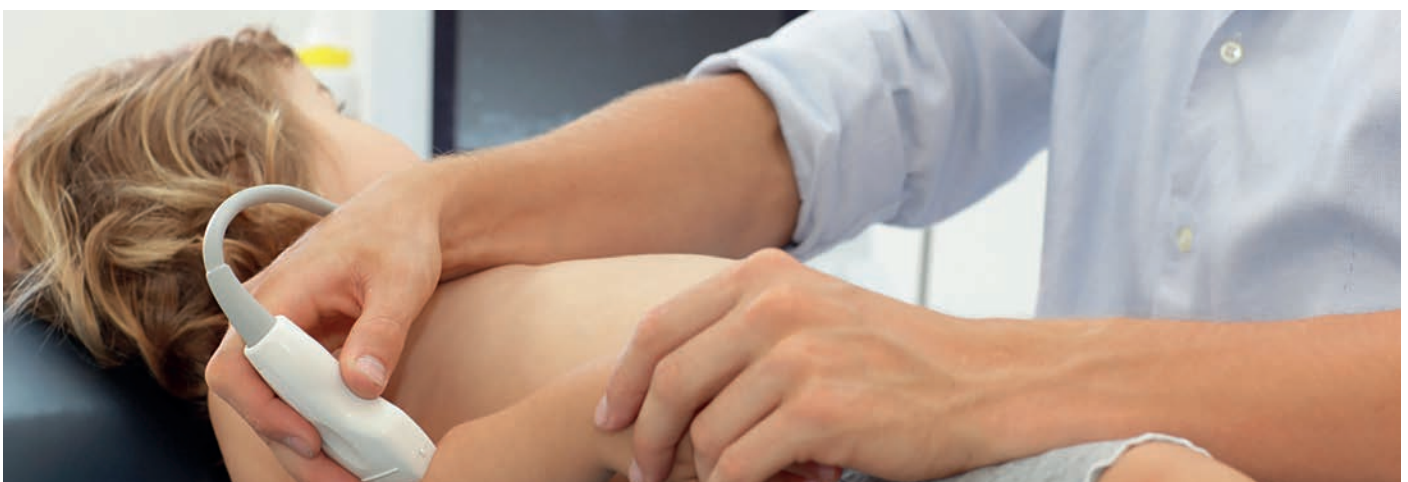

Photo: vascern.eu/wp-content/uploads/2019/10/VASCERN-FLYER-UK-HD_02092019_VF.pdf

Generated with www.qrcode-monkey.com

The VASCA WG

Prof. Guillaume Jondeau, Marine Hurard, Natasha Barr, Karen Daoud and Ibrahim Donmez

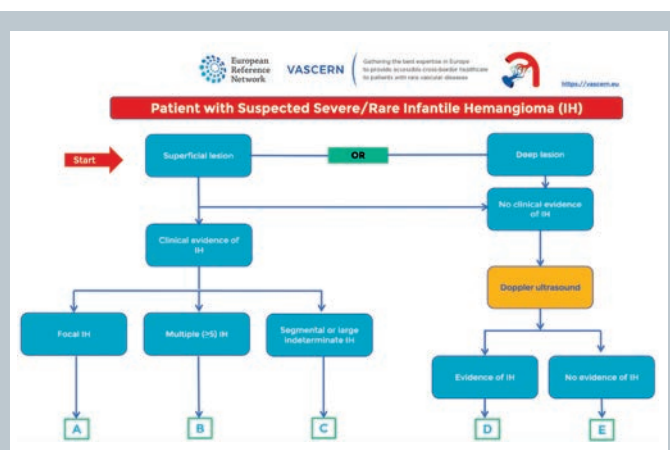
The Vascular Anomalies Working Group (VASCA WG), one of VASCERN's 5 Rare Disease Working Groups, focuses on vascular anomalies. Vascular anomalies include capillary, lymphatic, venous, arteriovenous and combined malformations, and are a highly variable group of diseases that can also occur in syndromes.

Many are very visible on the skin while others can be hidden in internal organs such as the liver, lungs and the brain, so no two patients are identical. While a few familial forms of vascular anomalies exist, most cases occur sporadically (i.e. are not inherited) and involve somatic mutations (i.e. occurring in only some localised cells of the body and not in the reproductive cells). Recent genetic discoveries continue to improve our understanding of these diseases and have led to research into new treatments.

The VASCA WG, chaired by **Professor Miikka Vikkula**, is comprised of 7 full member Healthcare Providers (HCPs) from Belgium, the Netherlands, Finland, Germany, Ireland, Italy and Sweden and one Affiliated Partner member from Austria. The group will enlarge in 2021 to potentially include HCPs from new countries, such as France, Lithuania, Norway, Portugal and Spain. The ePAG is represented by ePAG Co-chair Caroline van den Bosch from the Netherlands and the VASCA ePAG consists of 15 patient organisations from 7 countries, with very involved patient advocates.

The VASCA WG has been very productive in all of VASCERN's work packages and has already created many valuable outputs for both healthcare professionals and patients. Notable examples include:

- **Four patient pathways** that are available on the VASCERN website for the following conditions: Severe/Rare Infantile Hemangioma, Venous Malformations, Capillary Malformations and Lymphatic Malformations. These "Care Pathways" are meant to guide healthcare



One of four patient pathways



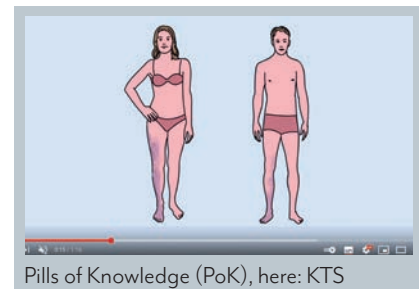
VASCA-WG meeting from 27 to 28 May 2019 in Brussels.

From left to right: Prof. Miikka Vikkula (Belgium), Dr. Nader Ghaffarpour (Sweden), Dr. Filip Farnebo (Sweden), Dr. Veronika Dvorakova (Ireland), Prof. Leo Schultze Kool (Netherlands), Dr. Carine van der Vleuten (Netherlands), Prof. Laurence Boon (Belgium), Prof. Paivi Salmonen (Finland), Dr. Anne Domp Martin (France), Dr. Friedrich Kapp (Germany), Dr. Eulalia Baselga (Spain), Prof. Jochen Rößler (Germany), Petra Borgards (Germany), Caroline van den Bosch (Netherlands), Maria Barea (Belgium), Dr. Andrea Diociaiuti (Italy)

professionals, unfamiliar with vascular anomalies, so that they can properly identify, diagnose and manage patients with these rare diseases.

- **Pills of Knowledge (PoK) videos by the VASCA WG**

include: Classification of Vascular Anomalies, Diagnostic Approaches for Vascular Anomalies, Multidisciplinary Expertise Teams for Vascular Anomalies and



Management of Vascular Anomalies. HEVAS (the Dutch Association for patients with Haemangioma and Vascular Malformations) has also been kind enough to produce various PoK videos that have been translated, revised and validated by the VASCA WG. These include videos on the lymphatic system & lymphatic malformations, treatment of lymphatic malformations, Klippel-Trenaunay syndrome (KTS) and, most recently, PIK3CA gene mutations and related vascular malformations.

- **The VASCA registry**, part of the VASCERN Registry project, is currently in development and is led by **Professor Leo Schultze Kool** (VASCA WG Co-Chair).

In the coming years, the creation of national networks will allow for more referral centres with expertise in vascular anomalies to be identified and they will be added to the VASCERN mobile app so that patients can easily find an expert centre nearby. The VASCA WG continues to be involved in many research projects that will advance the understanding of these rare diseases and lead to new discoveries and novel treatments for patients in the future.

VASCERN App

Prof. Guillaume Jondeau, Marine Hurard, Natasha Barr, Karen Daoud and Ibrahim Donmez

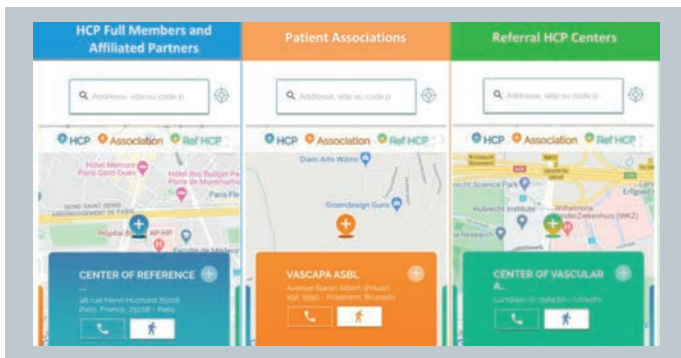
With the aim to facilitate cross-border healthcare within the European Union, VASCERN has developed a free mobile application, VASCERN App, to allow patients to search for the most competent Healthcare Providers (HCPs) as well as Patient Organisations related to their rare vascular disease.

VASCERN App was officially launched in January 2019 and a version 2 was released in August 2020. It is available on both IOS and Android. The structure of this mobile application has been translated into the 24 European languages for easier navigation and searching as well as disease names, which are also translated into various European languages.

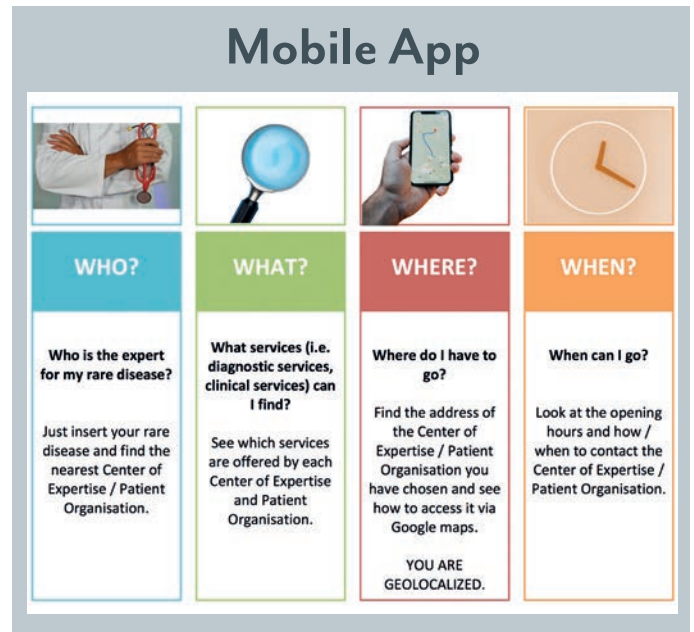VASCERN App currently gathers:

- **31 highly specialized multidisciplinary expert teams within VASCERN HCP Full Members and 7 Affiliated Partners** from the VASCERN European Reference Centers (both indicated as blue cards in the mobile application);
- **32 Referral HCP Centers**, which are centers that cooperate with the VASCERN European Reference Centers as part of the national networks and that can provide expert care to patients for rare vascular diseases to enable them to find the closest care to their home (indicated as green cards);
- **71 Patient Organisations** (indicated as orange cards).

Within this mobile application, you can look for your rare disease by typing its name in the search bar and thanks to geolocalisation, you will then be able to find the closest relevant HCPs and Patient Organisations in order to get all the information you need.



In order to better serve the rare disease community, VASCERN continues to improve its mobile application and include new HCPs and Patient Organisations from all over Europe with the goal of helping as many patients as possible.



Make sure to download VASCERN App today in order to find Europe's best rare vascular disease support and care at the end of your fingertips!

The app is available on IOS and on Android:




Photo: Lrex van der Heijden

Photo: vascern.eu/what-we-do/mobile-app/#1606920584872-1c3306b7-e0dc

Photo: vascern.eu/what-we-do/mobile-app/#1606920584872-1c3306b7-e0dc

Generated with www.qrcode-monkey.com

The CPMS (Clinical Patient Management System)

Prof. Leo J. Schultze Kool, MD, PhD, EBIR, Ibrahim Donmez and Caroline T. van den Bosch MSc

What is the CPMS?

The Clinical Patient Management System (CPMS) is a secure IT Platform that aims to support the European Reference Networks (ERNs) in improving the diagnosis and treatment of rare or low prevalence complex diseases across national borders of Member States in Europe. As a result it enables health professionals to enrol patients, upload medical documents, conduct video conferences and collaborate.

Leo Schultze Kool coordinates the CPMS for the VASCA-WG each month, he elaborates some more about this platform:

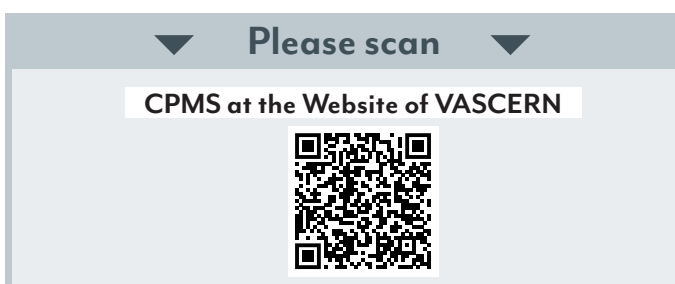'CPMS is a highly technical, extensive, web based Clinical Software Program, developed by OpenApp, the EU, DG Sante and the ERNs. The program entails many features like DICOM viewers for medical imaging, possibilities to upload and view pathology slides, and contains extensive virtual conferencing tools.

CPMS will realise one of the ERNs core tasks; bringing expert specialised care to all patients in Europe. The needed expertise can travel to the patient, instead of the other way around.'

Safety

The program was built in accordance with the EU GDPR standards for privacy and also only anonymous patient data can be entered.

It is a highly secure platform offering health care professionals a safe environment.



Who has access?

Only health care professionals who are member of the ERN can make use of the system. Non members can only enter as a guest in order to make it possible to attend the discussion of their submitted patient. Patients do not have access to the platform.

How to request for a consultation as a non-member?

Schulte Kool explains the procedure if a doctor from outside the ERN wants to submit a case to CMPS: 'The national VASCA member should be contacted first by the health care provider. If the national VASCA member feels the case should be discussed in the ERN, assistance will be asked from the central VASCERN coordinating office in Paris for uploading of the case. If there is no member at a national level the coordinating office can be contacted directly.'

CPMS within VASCERN

In 2020, we had thirty-five cases in total uploaded into the CPMS by VASCERN members and seven of those were uploaded by VASCA-WG members. Cases are uploaded into CPMS every month and as result VASCERN is one of the most active ERNs in terms of CPMS usage.

Experience so far within VASCA

'The program is mainly used for discussion of cases within the VASCA Workgroup members, the number of patients offered for consultation by non-members is still limited', explains Schultze Kool. 'However, since the start the number of discussed cases has steadily increased, partly caused by a learning curve and also because improvements were made to make the program more user friendly.'

Present limitations

Although CPMS is considered one of the most important practical and political tools of the ERN, Leo Schultze Kool signals some limitations: 'The consultations require a considerable time investment from those doing the consultations. This is additional to the already heavy patient loads in each hospital. The absence of reimbursement, time constraints etcetera are a severe limitation for further expansion of the platform. It is

however envisioned that national health insurance companies will accept the consultations by the CPMS as a valid form of second opinions. If these second opinions are acknowledged, the reimbursement obtained can be used for investment in further capacity and manpower expansion of the CPMS platform.'

The highlight of the year has been that VASCERN conducted two external guest cases from Portugal and Serbia via the CPMS and an outcome document was produced for both cases.

There is a process in place for external cases to be discussed via the CPMS for VASCERN, which can be found on the VASCERN website on the dedicated CPMS page. Furthermore, over the course of 2020, eight video conferences were conducted via the CPMS and seven of those were conducted by members of the VASCA-WG.

CPMS Tutorial Videos

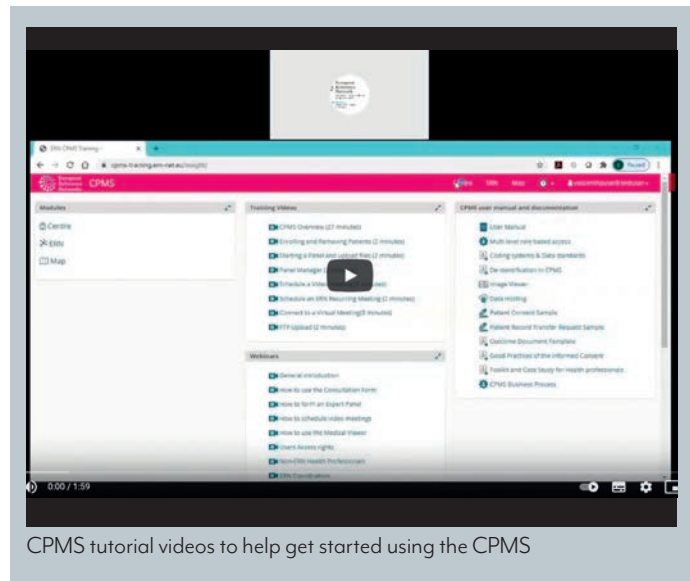


Photo: VASCERN

How does it work?

A) Create an account

C) Obtain patient's consent form

E) Conduct a virtual panel with other experts

B) Get trained by Helpdesk

D) Enrol a patient

F) Produce an outcome document

Photo: VASCERN

Leo J. Schultze Kool MD, PhD, EBIR
 Professor of Interventional Radiology
 co chair vasca
 chair registry WG vascern
 vice president ISSVA
 board member governing body EJP-RD
 Leo.Schultzekool@radboudumc.nl
 coordinating office
 vascern.coordination@aphp.fr

Ibrahim DONMEZ
 VASCERN - IT Helpdesk & End User Support
 Specialist
 AP-HP
 Hôpital Bichat 46 rue Henri Huchard
 75018 Paris
 ibrahim.donmez@aphp.fr

Registries for Rare diseases - An integral part of the EU policy for rare diseases

Prof. Leo J. Schultze Kool, MD, PhD, EBIR

Introduction:

Around the world thousands of different databases and registries exist, with a wealth of information. However, most of the times they can not be accessed. This is especially true for rare diseases where, due to the rarity of the disease, collaboration and combining of data is essential to further gain insights in the disease. Also, for the development and evaluation of new treatments, these combined data are absolutely needed. Combining data from different registries or databases is however almost impossible, as the location of the registries (which hospital/ which country), or even the existence of the registry is not clear and even if found, combining data is heavily complicated due to use of different databases/ structure of the database and terminology and privacy issues.

In 2016 a new principle was described (FAIR principle) which allows, after implementation in databases, that databases/ registries become 'machine readable'. The FAIR principles rapidly spread among researchers and got major support from major institutions (for instance, FDA, National Institute of Health, the National Cancer Institute) but also governments (EU and G7 meeting). It is now widely accepted and it will become the standard for future databases/registries. The EU has recognised the development and the advantages at an early stage and has supported and invested in the further development and introduction of the FAIR principle, not only for rare diseases or health in general but also for 7 others not health related domains like agriculture and economics.

So, what is FAIR?


≡ Fair stands for **F**indable, **A**ccessible, **I**nteroperable and **R**eusable.

Explained in simple terms: Databases or registries are made 'machine readable' or interoperable by adding an 'additional layer' to the registry. The layer defines, by applying a semantic model and ontologies, what sort of information is in the registry in machine readable language (RDF). On the outside the registry looks like a normal registry but due to this added layer all the content is machine readable and can be read by computers.

The database itself however has to be found if searched for it on the internet. This is done by creating and linking the database to a FAIR datapoint. The FAIR datapoint can be seen as a form of an antenna visible for computers on the internet. The **F**indable in FAIR: Information about the registry is stored in the FAIR datapoint also in a machine readable format (what sort of registry, who is the owner, who needs to approve access,

what sort of disease, how many records etc.) and can therefore be found if searched for on the internet.

Access can also be defined in the FAIR datapoint ranging from: contact the owner of the database if you would like to have access, to automatically granted access. The **R** in Reusable is mainly focused on secure long-term storage and remaining accessibility.



Leo J. Schultze Kool, MD, PhD, EBIR

Photo: Leo J. Schultze Kool

What did the EU do?

The EU was and is highly instrumental with the development of the European network for rare diseases and considers the registries as one of the major and essential steps to improve patient care for rare diseases across Europe. Major investments were made by the EU. The start of the European Joint Project for Rare Diseases (the EJP-RD) in which registry development and support are a major component. The development of the ERDRI platform by the JRC, incorporation of rare diseases in future EU grant developments, building of health digital data-spaces, but also discussing plans to further incorporate EU developments in national health care initiatives.

What did the ERNs do?

All ERNs are working closely with the EJP-RD platform and the data stewards' teams to start the FAIR based registries. Also, the ERNs applied for an EU grant which provided some financial support.

What was decided was that all ERNs will include a subset of data (the common dataset) in all ERN databases and which will enhance search possibilities between the different ERNs. This subset is consisting of 8 different questions (like gender, diagnose, gen coding, etc.). The progress made, differs between the different ERNs, however by having joined EJP RD online session experiences and knowledge are shared as much as possible.

The building of all the registries, defining disease specific elements, the *fairification* and all necessary steps for approval by ethics committees on local but also on national level, the approval by the individual hospital administrations will take several years to complete.

What did VASCERN do?

The transversal Working Group Registries coordinates the registry developments between the different working groups within VASCERN. There are monthly WebEx meetings for support of the involved data stewards, while the meetings are also used to identify key issues which needs input from the EJP RD. The meetings are also used to disseminate the latest news on the registry's developments in the other ERNs. The central coordinating team of VASCERN (located in Paris) provides a strong support with the grant applications, the writing and with the necessary reporting to the EU. Both the transversal WG and the central coordinating office are the backbone for all the developments within VASCERN.

What did VASCA do?

VASCA is one of the Working groups of the ERN VASCERN dedicated to vascular malformations.

In the past few years VASCA, but especially the Radboud team in Nijmegen (Netherlands) has been one of the early adaptors and developers of the FAIR principle.

Team members are heavily involved in the different working groups of the EJP RD not only in the semantic modeling for the fairification but also for the setup of FAIR datapoints and the further development of the health train principle for querying federated databases. For VASCA the registries were designed according to the federated approach, meaning each HCP stays in full control over its own data and only after approval local queries can be run through the FAIR data points.

The last year the following was developed in collaboration with multiple partners:

1. The common data set was made interoperable by designing a semantic model.
2. The now interoperable set was linked in rdf (a computer language) to the CASTOR registry.
3. The registries were registered on the ERDRI platform.
4. CASTOR was selected as our preferred database and formal agreements signed.
5. The ISSVA classification was made interoperable and links to different ontology databanks were incorporated.
6. Instructions for use for the common data set were written (close collaboration with a patient representative).
7. Data governing agreements for all the different HCPs were prepared.
8. Informed consent and the pseudo anomisation tools were further investigated and adapted.
9. First patients were entered at the Radboud HCP.
10. Start with implementing the registries in the local HCPs (approval local ethics committee, local hospital IT etc.).
11. First steps were taken to incorporate the OVAMA patient related outcome measurements in the registries.

Future prospect

Although still major steps have to be taken, the future looks promising and it is to be expected that within a few years a functioning registry system will become an essential part of VASCA.


Linking with the local hospital information system for an automated download of essential patient information with strict adherence to privacy considerations will be the next step and is already been discussed.

Please support our work with a donation!

We rely on donations to continue supporting people affected with vascular anomalies and to be able to present future issues of the VASCA Magazine.

Link to donation page:
www.whyonate.eu/fundraising/vasca-magazine

Thank you!



'Patient Journeys': improving care by patient involvement

Lay description of the article in *European Journal of Human Genetics* 4 Dec. 2019*

The relationship between a patient and a healthcare provider has changed over the last decade enormously. In the area of rare diseases, often the patient knows more about their condition than the doctor who is treating them, and this is precisely not what the patient is looking for. Patients, and their families, have to deal with a lot of challenges during their healthcare journey. This starts with the medical diagnosis, treatment and next steps. The patient journey is marked by uncertainty, no effective medical treatments and many unanswered questions.

The reason that this journey is so difficult, is because there is little knowledge regarding rare diseases. Despite there being approximately 7000 rare diseases identified worldwide, medical professionals may only see a few patients with a rare disease during their entire career.

Although patients are involved in a number of successful initiatives, such as the development of clinical guidelines, integrating the patient's experiences and their needs into the development of healthcare services has generally been less successful. To improve care for patients with rare diseases, we must collect the available knowledge and experience not only from the medical experts but also from the patients. Communication between patients and doctors particularly needs to be greatly improved. The single and most important aspect in assessing the quality of healthcare is patient satisfaction and their experiences with medical professionals. This data can even be used to predict survival rates. Meeting the patient needs and to improve the quality of services in a better way is achieved by patient involvement in the design, evaluation and designation of healthcare services.

Since March 2017 the European Reference Networks (ERNs) have been announced with the main goal to connect European experts in order to gather their collective knowledge and expertise. The data and information collected can then be accessed by patients worldwide.

The ERN Genturis (genetic tumour risk syndromes) started with a visual representation to share their knowledge and experience by means of a 'Patient Journey' (PJ). The PJ collects the common needs of a patient by mapping their needs across the series of stages of the PJ. The PJ is intended to connect expert guidelines, medical interventions, screening and treatments. The PJ not only pays attention to the medical

aspects but also to the psychological aspects. The PJ's are built for each disease and describes the applicable stages of this particular disease. Each stage covers the clinical presentation, the patient's challenges, needs and their objective to improve the care. When the PJ is finished this is reviewed by patients and professional experts. By using graphics, patients and healthcare providers can discuss the personal needs of a patient paying attention at the same time to the expertise of both patient and professional leads.

The objective remains: improving care for patients with a particular rare disease.


A PJ encourages experts to use national guidelines and to identify the need for evidence-based European guidelines that should result in equal care to every rare disease patient. A PJ is a personal testimony that shows the patient's needs by means of a graphical representation and a table holding the details. The PJ is intended to show the objectives for both patients and healthcare providers. Healthcare providers can use the PJ to explain to new patients the clinical roadmap. Patients can use the PJ to determine specific needs within the roadmap.

A PJ can be developed in several ways. One way is to develop surveys and send these to patients and families. In this case great care must be given to the privacy of the medical data, consents and utmost confidentiality. This, however, is a time-consuming option. Another approach is to compose the PJ based on personal experiences of, for instance, someone who has experienced a number of cases. Data can be verified, for example, at a workshop during which new experience are shared. The verification with the healthcare professionals can be performed in parallel with the verification by patients.

* Editorial's note:

This article is published with open access von Matt Bolz-Johnson, Jelena Meek, Nicoline Hoogerbrugge
Received: 7 August 2019 / Revised: 4 October 2019 / Accepted: 1 November 2019 © The Author(s) 2019.

[The complete article can be found online:](#)



'Patient Journey' Cutis Marmorata Telangiectatica Congenita

Lex van der Heijden (CMTC-OVM)

A 'Patient Journey' is a testimony that reflects the natural history/needs of patients and their families for a specific rare disease. It represents the collective perspective on the burden of the disease and the needs of people with the first-hand experience of living with a rare disease.

About CMTC

Cutis: skin | Marmorata: marbeled | Telangiectatica: abnormal bloodvessels | Congenita: present at birth | Occurrence: unknown | CMTC is both a skin disease as well as a vascular malformation.

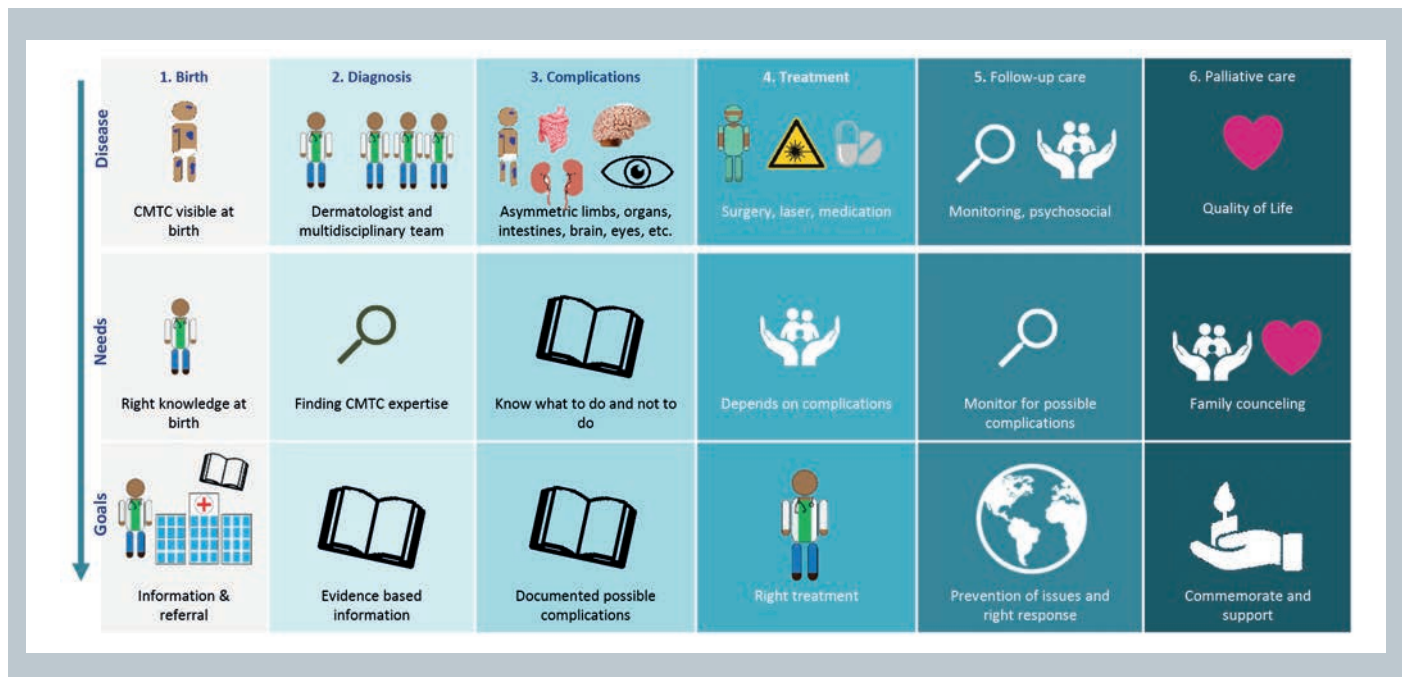


Photo: Lex van der Heijden, CMTC-OVM


Overall patients and families needs across the six stages

- Immediate access to diagnosis by a multidisciplinary team in the right medical expertise center.
- Psychological and psychosocial support.
- Peer support from patient organisations.
- Access to reliable and understandable information on the disease and treatment plan.
- Understand the treatment options (dos and don'ts) and the social impact on patients' future life.
- Information about the risks, the expected results and each step of the treatment.
- Financial support if the costs for treatment and surgery are not reimbursed.
- Smooth transition from care to home.
- Best holistic care approach.

- Access to quick psychological and psychosocial support.
- Direct contact with patient organisations.
- Social inclusion programmes offered by the schools to inform and facilitate the integration of the children.
- Smooth transition from child care to adult care.
- Medical data record in one single platform and accessible for the patients and families.
- Access to other treatments (camouflage technique instead of laser).
- Access to the best medical and palliative care services.
- Medical and genetic data available for further research.
- Creation of a social media memoriam page.

The complete CMTC Patient Journey can be found online:

Generated with www.qrcode-monkey.com



Overall patients and families ideal care and recommendations across the six stages

- Timely diagnosis in a reference medical center.
- Access to information material on disease and treatment plan.

About ISSVA

Prof. Leo J. Schultze Kool, MD, PhD, EBIR and Caroline T. van den Bosch MSc

It all started in 1976 with Drs. John Mulliken and Anthony Young who had a mutual fascination for vascular anomalies an at that time poorly understood disease entity (at that time every vascular lesion was called a hemangioma). Suggested by Dr Murray, at that time chief of Dr Mulliken, Mulliken and Young initiated a series of biannual international workshops called 'International Workshop for the Study of Vascular Anomalies'. The first meetings were in Boston (1976/1978) followed by London (1980), Paris (1982), Milan (1984), Boston (1986), Hamburg (1988), Amsterdam (1990) and Denver (1992). At the meeting in Denver the name of the meetings was changed to 'The International Society for the Study of Vascular Anomalies (ISSVA)', bylaws were written and approved at the next meetings and ISSVA was founded as society.

Today ISSVA is a thriving society with ISSVA workshops held all over the world. Hundreds of international specialists of a wide range of medical disciplines, all involved in the treatment of patients with vascular anomalies, attend these meetings and the numbers of attendees are growing continuously. ISSVA membership is open for all who support the fundamental mission of the organisation; to improve the lives of patients with vascular anomalies. Those includes dedicated physicians/scientists, nurses and patient representatives. More information about the society can be found at the website of the society.

ISSVA Workshop locations

1976: Boston, United States
 1978: Boston, United States
 1980: London, UK
 1982: Paris, France
 1984: Milan, Italy
 1986: Boston, United States
 1988: Hamburg, Germany
 1990: Amsterdam, Netherlands
 1992: Denver, Colorado, United States
 1994: Budapest, Hungary
 1996: Rome, Italy
 1998: Berlin, Germany
 2000: Montreal, Quebec, Canada
 2002: Nijmegen, Netherlands
 2004: Wellington, New Zealand
 2006: Milan, Italy
 2008: Boston, United States
 2010: Brussels, Belgium
 2012: Malmö, Sweden
 2014: Melbourne, Australia
 2016: Buenos Aires, Argentina
 2018: Amsterdam, Netherlands
 2020: Virtual Meeting

The current board of directors (2020) consist of the following persons

1. President: Tony Pennington, Australia.
2. President-elect: Francine Blei, USA
3. Past-President: Ilona Frieden, USA
4. Vice-President: Leo Schultze Kool, Netherlands
5. Secretary: Denise Adams, USA
6. Treasurer: Juan-Carlos Lopez-Gutierrez, Spain
7. Scientific committee chair, Dov Goldenberg, Brazil
8. Editor in Chief: Gresham Richter, USA
9. Member at Large: Miikka Vikkula, Belgium
10. Member at Large: Michel Wassef, France
11. Member at Large: Annouk-Anne Bisdorff-Bresson

The President serves for a period of two years. He will then become Past-President and the President-elect will become President. The former Pas-President will leave the board and a new President-elect will be voted for in the General Assembly.

Mission of ISSVA

'ISSVA is a multidisciplinary international society of physicians, scientists, and health care providers united by an interest in vascular anomalies. The society aims to promote the highest standards of care for patients with vascular anomalies by advancing clinical and scientific knowledge concerning causes, diagnosis and treatment, and by education of physicians, health care providers, patients and the community. The society encourages the free flow of information between its members and interested groups, through workshops, online meetings, webinars etc.'



Patient Advocacy Organisations

Since the establishment of ISSVA in 1992, collaborations have been integral to the growth, awareness and improved diagnosis and treatment of patients with vascular anomalies. In addition to fostering collaboration amongst individual members representing a wide variety of specialties and geographic regions, ISSVA also networks with patient advocacy

organisations. These organisations support ISSVA's initiatives and are a key contributor to providing patients with valuable educational resources while advocating for individuals with vascular anomalies.

Website

ISSVA has its own website, which is frequently updated with information concerning meetings, newsletters, the classification etc..

The Journal (JoVA)

One of the recent accomplishments of ISSVA is the start of its own journal fully dedicated to vascular anomalies. (2021) Gresham Richter is the editor in chief of this open access, online journal which is expected to become THE journal for all working in this field.

ISSVA Classification

As many different diagnosis were used to describe the different vascular anomalies making communications and even research activities between researchers difficult, one of the first tasks of the society was to develop a common language to describe the different diseases. Two different schools of classification existed (the French-American and the Hamburg school). After a long discussion between ISSVA members the first was adopted as the classification. The classification based on Pathology makes a distinction between vascular tumors and vascular malformations. For those interested the full classification can be found on the ISSVA website, an example is shown in the figure above right.

ISSVA classification for vascular anomalies ©
 (Approved at the 20th ISSVA Workshop, Melbourne, April 2014, last revision May 2018)
 This classification is intended to evolve as our understanding of the biology and genetics of vascular malformations and tumors continues to grow

Overview table

Vascular anomalies				
Vascular tumors	Vascular malformations			
	Simple	Combined *	of major named vessels	associated with other anomalies
Benign	Capillary malformations	CVM, CLM	See details	See list
Locally aggressive or borderline	Lymphatic malformations	LVM, CLVM		
	Venous malformations	CAVM*		
	Arteriovenous malformations*	CLAVM*		
Malignant	Arteriovenous fistula*	others		

* defined as two or more vascular malformations found in one lesion
 * high-flow lesions

A list of causal genes and related vascular anomalies is available in [Appendix 2](#)

The tumor or malformation nature or precise classification of some lesions is still unclear. These lesions appear in a [separate provisional list](#).

[Abbreviations used](#) [For more details, click on the underlined links](#)

Ref: www.issva.org. Part of the text is from this website

The classification is not a static one but is regularly updated according to new insights (last update was 2018).



ISSVA Workshop Amsterdam 2018
 From left to right: Amalia Utami MD, Maria Jongma (Hevas), Prof. Chantal van der Horst, Prof. Laurence Boon, Prof. Leo Schultze Kool, Prof. Miiikka Vikkula, Caroline van den Bosch (Hevas)

Photo: Caroline van den Bosch

Current Issue

December 2020 - Volume 1 - Issue 1

Editor-in-Chief: Dr. Gresham Richter
ISSN: 2690-2702
Online ISSN: 2690-2702
Frequency: Continuous Publication

Ref: www.issva.org. Part of the text is from this website

*** Editorial's note:**
 Part of the text is from this website:
 ○ www.issva.org

Please scan

Website

Generated with www.qrcode-monkey.com

Comment on 'Cutaneous Infantile Haemangiomas with Intracranial and Intraspinal Involvement: An European Multicentre Experience and Review.'

Dr. Andrea Diociaiuti et al. *Acta Derm Venereol.* 2020 Sep 8;100(16):adv00255

Infantile haemangioma (IH) is the most common tumour in infancy and affects 5-10% of infants. It is usually on the skin, but localisations in internal organs are possible. The propranolol era has revolutionised the approach to treatment of this tumour. Very few cases of central nervous system (CNS) IHs treated with propranolol have been described in literature. The authors report a series of 7 patients affected with cutaneous and CNS IH treated with propranolol.

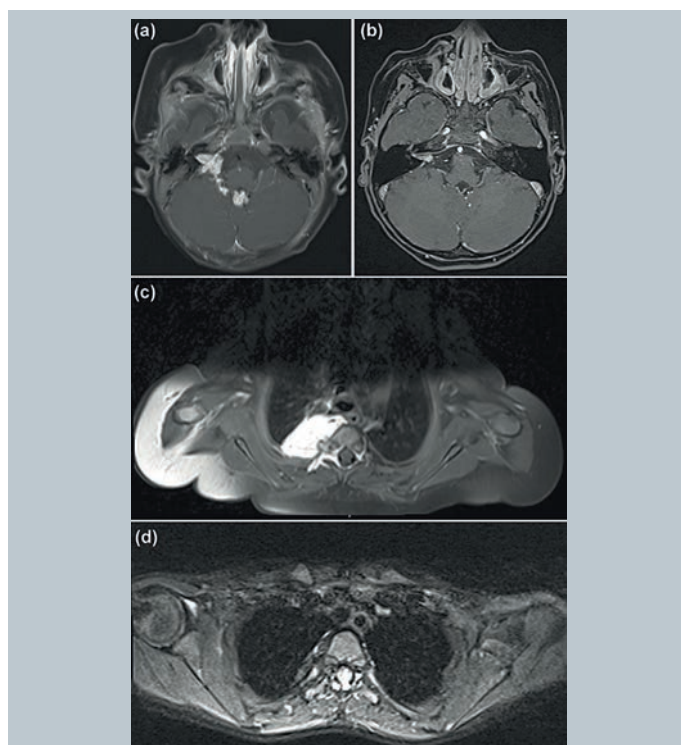


Fig. 2 from 'Cutaneous Infantile Haemangiomas with Intracranial and Intraspinal Involvement: A European Multicentre Experience and Review.' by Diociaiuti A, et al. *Acta Derm Venereol.* 2020 Sep 8;100(16):adv00255: Axial post-gadolinium T1WI of posterior fossa before and after treatment. (a) A well-circumscribed extra-axial contrast enhancing mass located in the right cerebellopontine angle cistern extending to the internal auditory canal and through the foramen of Luschka to the fourth ventricle. (b) An almost complete resolution of the lesion; only a small contrast enhancing nodule is evident in the internal auditory canal. (c) Axial post-gadolinium T1WI of the thoracic spine before and after treatment: a contrast enhancing mass located in the right costo-vertebral angle with intraspinal (extradural) extension through the neuroforamen. (d) Complete resolution of the lesion.

Photo: 'Acta Derm Venereol'

Patients with intracranial or intraspinal IHs were collected from a multicenter study between 2015 and 2019. Four European reference centers for vascular anomalies were involved in the study: 2 Italian (Bambino Gesù Children's Hospital, Rome and University of Bologna), 1 Spanish (Hospital de la Santa Creu i Sant Pau, Barcelona) and 1 French (Bordeaux University Hospitals). The patients, affected with large segmental IH underwent imaging in order to exclude PHACES or LUMBAR/ SACRAL

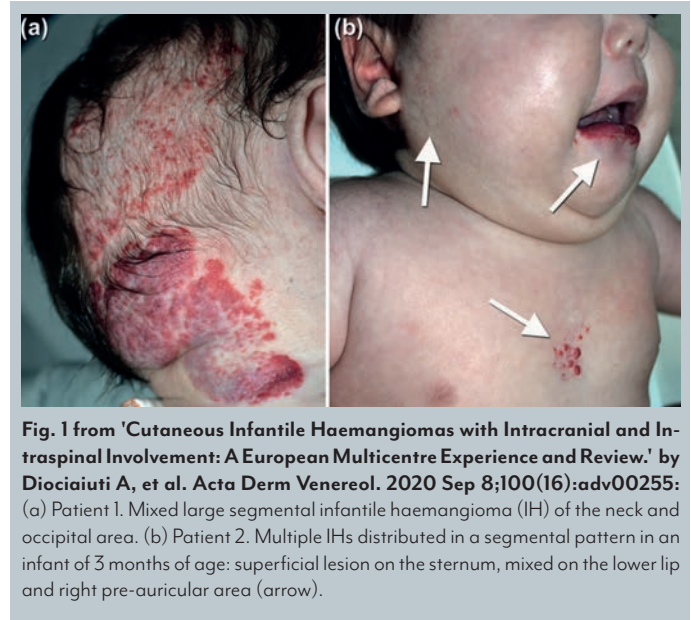


Fig. 1 from 'Cutaneous Infantile Haemangiomas with Intracranial and Intraspinal Involvement: A European Multicentre Experience and Review.' by Diociaiuti A, et al. *Acta Derm Venereol.* 2020 Sep 8;100(16):adv00255: (a) Patient 1. Mixed large segmental infantile haemangioma (IH) of the neck and occipital area. (b) Patient 2. Multiple IHs distributed in a segmental pattern in an infant of 3 months of age: superficial lesion on the sternum, mixed on the lower lip and right pre-auricular area (arrow).

Photo: 'Acta Derm Venereol'

syndromes. All patients underwent oral propranolol treatment between 2 and 3 mg/kg/day.

Two cutaneous IHs were located on the sacral and lumbar area and associated with an intraspinal IH, while the others were on the head and/or face (Fig. 1a) with an intracranial component (Fig. 2a) except one patient with an intraspinal involvement (Fig. 1b, 2c). One patient showed an IH on the right buttock with an intra-spinal involvement associated with a malformation of the terminal part of the spinal cord.

Five patients had a complete or almost complete resolution of the cutaneous IHs after propranolol treatment. All CNS IH responded to propranolol (Fig. 2b, d) and the patient with malformed spinal cord successfully underwent neurosurgery.

There is an under esteem of CNS IH due to the frequent absence of symptoms in these patients. Indeed, their diagnosis is usually incidental during imaging for large segmental IHs in order to exclude PHACE and LUMBAR syndromes.

Prior to our study only 13 cases of intra-CNS IH have been reported. Even if our patients were asymptomatic, other patients with severe neurological symptoms have been described in literature demonstrating that this localisation is potentially at risk for complications. In these cases rapidly involuting congenital haemangiomas and other vascular or non-vascular tumours should be ruled out in the differential diagnosis.

Our experience suggests that intracranial MRI should always extended to the spine. Moreover, as already known, propranolol has the property to pass the blood-brain barrier. For this reason this particular beta-blocker, first line treatment for IH, has been effective also in intra-CNS lesions. These data suggest that oral Propranolol should be considered for this rare localisation to avoid possible complications.

Infantile haemangioma

Comment by Andrea Diociaiuti, MD, PhD on Christine Léauté-Labrèze, John I Harper, Peter H Hoeger* (Lancet, 2017 Jul 1;390(10089):85-94.)

The article of Dr Leauté-Labreze's is a review on infantile hemangioma (IH). Although it dates 2017, we chose it because it is a complete and exhaustive paper on this topic. We will focus on those aspects related to rare forms. IH itself is not a rare vascular tumour and has a prevalence of 4-5% in infants. It is generally a benign and self-resolving neoplasm, but there are some cases that must be treated. In addition, some forms are extremely rare and are a true challenge for doctors.

Complications for which treatment is indicated are due to a particular location of the lesion, its size or its intrinsic characteristics:

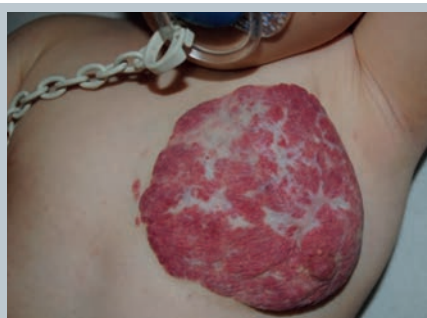- Obstructional and functional impairment, when located close to eyes, nose, mouth, perianogenital region, hands, larynx. In the latter case it represents a real medical emergency.
- Ulceration resistant to common treatments.
- Disfigurement in particular of the face.

When segmental hemangioma is located in the midline area on the perinatal or lumbosacral region it may be associated with urogenital, anorectal, vascular abnormalities and spinal defects.

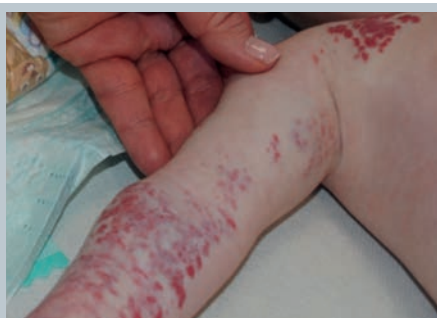Treatment

The treatment of IH today is indicated for all the above complicated forms and propranolol is the first line drug. It has been widely tested and demonstrated safeness and effectiveness. The response is obtained in 96-98% of cases with a complete or almost complete regression in 60% of cases. Among the most common side effects sleep disorders, sleepiness and irritability. Bronchospasm and bronchiolitis are rarer and should lead to discontinuation of the drug. Hypoglycemia, bradycardia and atrioventricular block are absolute contraindications to the drug. There are also other beta-blockers on the market that do not pass the blood-brain barrier unlike propranolol, but they have not yet been adequately tested and are still

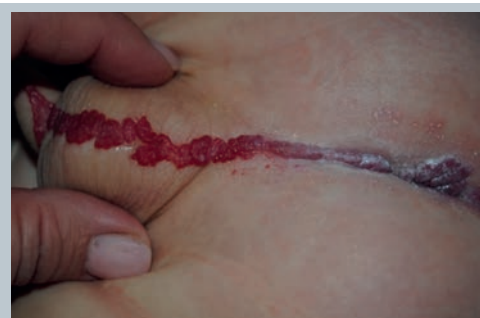Photo: Bambino Gesù Children's Hospital



Large IH of the breast (may have hypothyroidism or cardiac failure)



Segmental IH of upper arm and shoulder (may have PHACE Syndrome)



Segmental midline IH (may be LUMBAR)

In addition, there are multifocal forms that can affect the liver. These may be associated with hypothyroidism in 21% of cases and in rarer cases with high-output cardiac failure. There are also rare segmental forms that when localised on the face and when exceed 5 cm in size can be associated with extracutaneous malformations: PHACES syndrome. The associated anomalies are summarised in the acronym: being posterior fossa malformations; haemangiomas; arterial, cardiac, and eye anomalies; and sternal or umbilical raphe. The anomalies of the cerebral vessels and the aortic arch are the most frequent and the greatest risk is to develop a stroke.



Andrea Diociaiuti, MD, PhD

Photo: Andrea Diociaiuti

considered off-label. In conclusion, significant progress has been made in recent decades in the knowledge and treatment of IH. Propranolol has been approved by both the US Food and Drug Administration and European Medicines Agency for the treatment of complicated hemangiomas. For the future it is essential to improve education of primary care physicians and pediatricians. In fact, the early referral of patients with potentially complicated IH to treatment is critical for the successful outcome, so that the tumor does not cause difficult to treat complications and disfigurements.

Andrea Diociaiuti, MD, PhD
 Resp. UOS Centro delle Dermatosi Croniche
 Complesse e Genodermatosi
 UOC Dermatologia
 Bambino Gesù Children's Hospital
 Rome, Italy
andrea.diociaiuti@opbg.net

PROS syndrome

Over the past decade many types of vascular malformations have been associated to somatic activating mutations in the PIK3CA gene. Some of these vascular malformations are accompanied by segmental overgrowth and deformities of the musculoskeletal system and/or abnormalities of skin.

Vascular malformations can cause infection, pain, and lead to an increased risk of thromboembolic events in the whole body. In addition, some of the patients have neurological symptoms. Before the identification of mutations in the PIK3CA (the phosphatidylinositol-4,5-bisphosphate 3-kinase) gene, patients were classified based on the diversity of the phenotype, into different syndromes. Nowadays it is known that all these different syndromes have a similar underlying cause, namely a mutation in the PIK3CA gene.

Based on the mutations found in the PIK3CA gene, this group of patients with overgrowth and vascular malformations are called PIK3CA related Overgrowth Spectrum (PROS). This means that for example the following different clinical entities now are called PROS syndrome.

- Klippel-Trenaunay Syndrome (KTS)
- Congenital Lipomatous Overgrowth, Vascular Malformations, Epidermal nevi, Scoliosis/skeletal and spinal abnormalities (CLOVES syndrome)
- Isolated Lymphatic Malformation (ILM)
- Megalencephaly-Capillary Malformation (MCAP)
- HemiMegalEncephaly (HME)
- HHML (HemiHyperplasia-Multiple Lipomatosis)
- Facial Infiltrating Lipomatosis FIL
- Fibro-Adipose Vascular Anomaly (FAVA)
- Macroductyly
- HemiHyperplasia (HH)
- FibroAdipose Hyperplasia or Overgrowth (FAO)
- Capillary malformation of the lower lip, lymphatic malformation of the face and neck, asymmetry of the face and limbs, and Partial or Generalised Overgrowth (CLAPO syndrome)
- Epidermal nevus, benign lichenoid keratosis, or seborrheic keratosis

Currently, diagnosis of PROS can be confirmed with genetic testing. However, this means that a biopsy of the affected part of the body has to be taken. This because such genetic mutation is not present in the whole body (mosaicism) and even in

D. Maroeska W.M. te Loo, MD, PhD



Photo: Dr. DMWWM te Loo

the parts of the body that are affected, the percentage of the genetic mutations of the PIK3CA gene can be low and difficult to detect. Tissues that can be affected are skin, vasculature, bones, fat and brain tissue depending on the specific phenotype. This phenotype can be very heterogenous in location and extent of overgrowth and the gradation and presence of vascular complications. Furthermore, the timing of the onset of the excess of growth can vary. Some patients will have this excess of growth during childhood, whereas others suffer during adulthood. Clinical symptoms vary, depending on the anatomical location of affected parts of the body, the extent of overgrowth and the presence of vascular malformations. For example, for those with brain involvement, clinical symptoms



Figure 1: The term PIK3CA related overgrowth syndrome can be seen as an umbrella covering multiple different disease phenotypes. Some of them are shown in this figure.

Photo: Dr. DMWWM te Loo

might be impaired cognitive function or epilepsy. Others will suffer of overgrowth of legs or arms leading to surgical interventions leading to impairment of mobility. Overgrowth of the feet will lead to difficulties finding the right shoes and even might lead to amputation.

Unfortunately, PROS cannot be cured. Treatment is focused on reducing the complications caused by the overgrowth and symptomatic treatment.

For example for those suffering of epilepsy, anti-epileptics are given to control seizures. Pain medication can be given to those suffering of pain due to the vascular malformation and surgery or sclerotherapy might control the growth of the vascular malformations. Surgery can be used to treat skeletal problems such as scoliosis.

Through the identification of the genetic alterations in the PIK3CA gene, however, the understanding improved of how this genetic alteration leads to the clinical phenotype. It became clear that the mutations found in the PIK3CA gene led to the activation of the mTOR pathway. mTOR is one of the main factors in the cell involved in cell growth, proliferation and angiogenesis (development of new vasculature). Interestingly, in different types of cancer the PIK3CA pathway is also activated due to somatic mutations of the PIK3CA gene. This has led to the development of treatment focused on this pathway. At the same time, this information was used for the treatment of patients with PIK3CA lesions.

Unfortunately, PROS cannot be cured. Treatment is focused on reducing the complications caused by the overgrowth and symptomatic treatment.

Furthermore, there is no evidence that patients with PROS syndrome have an increased risk to develop PIK3CA related cancer. Despite that, treatment used in patients with PIK3CA related cancer types, can be useful for patients with PROS.

One of the first medical agents directed against the PIK3CA-mTOR pathway is Rapamycin or Sirolimus and the first patients with PROS were treated in 2011.

Since then, it has become clear that Sirolimus is able to reduce complaints caused by the vascular malformations and in some cases was able to stabilise the overgrowth. Unfortunately, it was later found that at higher dosages Sirolimus can lead to unwanted serious adverse events. However, recent data of a clinical trial performed in the Netherlands shows that low dose Sirolimus gives a similar therapeutic effect without serious adverse events. This opens the opportunity to start treatment at a young age and continue treatment for a long time, even past puberty, to obtain a maximum benefit.

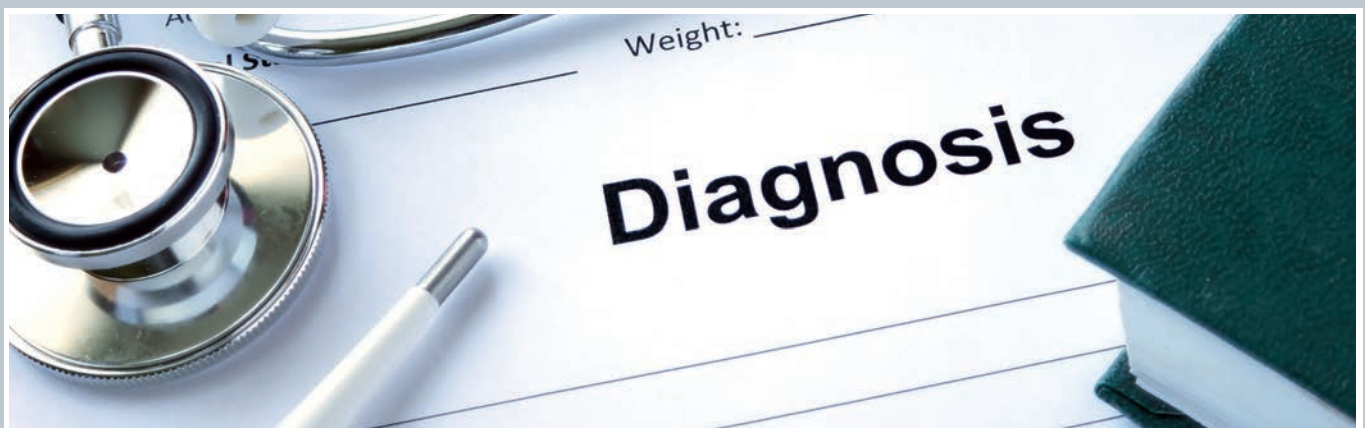Of more interest for patients with PROS may be the development of specific PIK3CA inhibitors like the drug Alpelisib, which has been approved for breast cancer. Venot and colleagues⁽¹⁾ have investigated the effect of the drug Alpelisib in a mouse model of PROS syndrome in France. Encouraged by the results, they treated 19 patients with Alpelisib. The results were surprising: in all patients improvement of the disease symptoms occurred. Adverse events observed were minimal, suggesting that Alpelisib might open doors for patients with PROS. The first step now to be taken is an international trial including a significant number of patients with PROS syndrome to reveal the true efficacy in PROS syndrome but also to gain insight in the frequency of adverse events occurring. Only if an adequate balance between risk of medication versus benefit of medication can be achieved, the right treatment for the right person can be found.

References

1. Venot, Q. et al. Targeted therapy in patients with PIK3CA-related overgrowth syndrome. Nature 558, 540–546 (2018)

D. Maroeska W.M. te Loo, MD and PhD
 Pediatric Hematologist and Clinical Pharmacologist
 University Hospital Nijmegen, Radboudumc
 ● Maroeska.teLoo@radboudumc.nl

Photo: LGD Alliance Europe - Fotolia 84707845



Cerebral cavernous malformations (CCM) and cerebral arteriovenous malformations (AVM) - Similar and yet quite different

Priv.-Doz. Dr. med. P. Dammann

Both CCMs and AVMs belong to the disease group of cerebral vascular malformations (VMs). VMs can stay asymptomatic for long periods of time, sometimes even lifelong. However, they are prone to intracerebral hemorrhage (ICH) or, less frequently, other blood-flow-related symptoms. Such hemorrhages can cause stroke-like symptoms, for example seizures or focal neurological deficits. Sometimes they can even be life-threatening. Upon diagnosis of a VM, clinicians need to balance the risk of an ICH (or other symptoms) and its potential impact on the patient and the perils of treatment. Such treatment is oftentimes invasive, like surgery or neuro-radiological interventions.

Although both CCMs and AVMs are malformations of the intracranial vessels, they affect different sections of the vascular system.

While CCMs arise from abnormal capillary vessels building up to centimeter-sized mulberry-like lesions filled with stagnant blood at *capillary pressure levels*, AVMs represent an abnormal connection between arteries and veins, bypassing the capillary system and being filled with blood at *arterial pressure levels* (which are, however, lower than systemic pressure levels¹). Both types of malformations may appear as circumscribed lesions but frequently involve and run through larger parts of the brain.

It is because of these basic features that, if a hemorrhage from such lesions occurs, it is usually more severe and disabling in AVMs.

Epidemiology

AVMs are very rare. The prevalence is estimated to be lower than 10.3/100.000 in the population², making it per definition a rare disease (<1/2000 people)³. In contrast, CCMs are much more frequently found. The estimated prevalence is estimated with 500/100.000 in the population. Depending on the study, it is approximately 10-50 fold higher than that of AVMs⁴. Merely a subgroup of CCMs, the familial form of the disease, is also considered a rare disease.

Imaging

Magnetic resonance imaging (MRI) is the imaging standard for both types of lesions, including the depiction of vessels (angio-

graphy) and normally the administration of contrast agents. In AVMs, a digital subtraction angiography (DSA) is performed in many cases to better visualise the malformation to assess risk factors for hemorrhage and evaluate therapy options.

Risk of hemorrhage

The exact risk of a 'rupture' or the occurrence of other symptoms of VMs is difficult to predict. This is due to the fact that we do not know how many people harbor an asymptomatic VM. Although the individual risk in a specific patient is even more difficult to predict, some studies have facilitated its estimation. Thus, the probability of an ICH in asymptomatic AVMs appears to be relatively low, at approximately 1%/year/patient⁵. The same accounts for asymptomatic CCMs⁶. Once bleeding has occurred, however, the risk of a second hemorrhage increases strongly in the acute phase after the event in both CCMs and AVMs. This "activation" of the VM is most often the reason to initiate treatment and prevent further bleedings. For example, the risk of a rebleeding is up to 30% over a 5-year period in CCMs⁶, and approximately 20% in the first year in AVMs⁷.

Severity of hemorrhages

There is a large difference between ICH from CCMs and AVMs regarding clinical outcome and case fatality. Case fatality, i.e. the mortality caused by a certain disease (in this case the ICH of the malformation and its consequences), is around

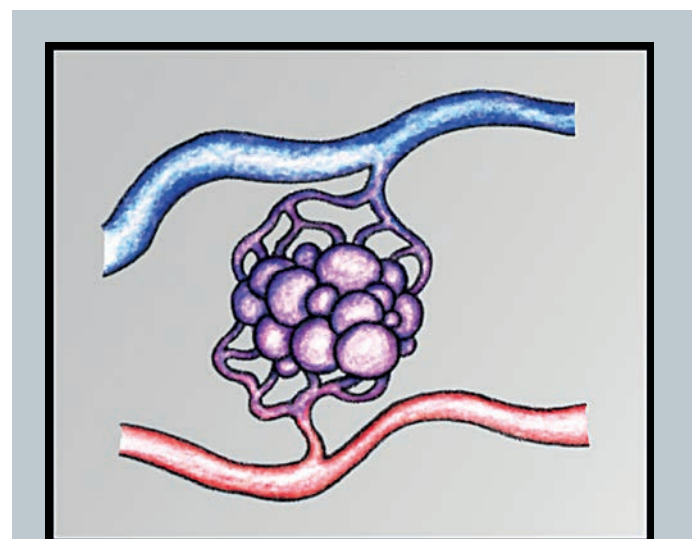


Figure 1: CCM
'Mulberry-like' circumscribed malformation arising from within the capillary system.

12% within the first year for AVMs⁸, while it is only 0%-4% for CCMs^{9,10}. A significant disability or death (modified Rankin Score >3) following an ICH appears in 40% of AVM patients⁸ and only in approximately 10% of CCM patients (mainly those with brainstem CCMs)¹⁰.

Risk factors for hemorrhage

As mentioned above, prior hemorrhage is the most consistent risk factor for both AVMs⁷ and CCMs^{9,11}. Further risk factors for AVMs include venous drainage patterns, nidus location, and presence of associated arterial aneurysms or venous varices⁷. Additional risk factors for CCMs include brainstem location and (potentially) female sex^{9,11}. The influence of other risk factors is still under investigation.

Treatment for AVM

There is strong consensus that once an AVM leads to ICH it should normally be treated to prevent further, potentially fatal, hemorrhage.

The form of treatment depends on the individual characteristics of the AVM and consists of surgery, embolisation, radiation, or a combinatory treatment. An interdisciplinary team of experts should assess which treatment option has the best risk-benefit ratio for each individual patient. Whether an asymptomatic AVM should be treated under certain circumstances is discussed controversially. The same accounts for AVMs that are symptomatic but did not cause an ICH (seizures, 'steal-phenomenon'). In these cases, highly individual decisions are necessary. If certain risk factors are diagnosed (especially associated aneurysms and venous varices), a treatment may also be indicated⁷.

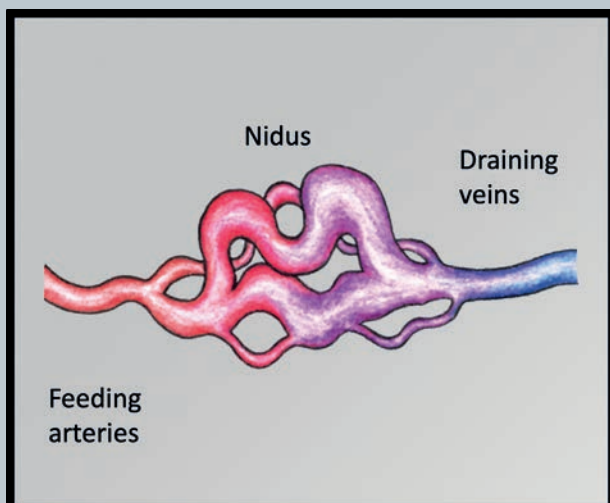


Figure 2: AVM
Direct arterio-venous malformation bypassing the capillary system (in the area of the so called nidus).

Treatment for CCM

It is generally accepted that asymptomatic CCMs should not be treated. In case of an ICH, indication for surgery must be carefully balanced.

There is quite strong evidence that younger patients with seizures caused by the CCM (with or without ICH) benefit from surgical treatment, gaining seizure freedom and being able to stop antiepileptic drug treatment^{12,13}. Nevertheless, especially in brainstem CCMs, indications for surgery are challenging as surgical treatment of these lesions is associated with significant operative risks. On the other hand, ICH may lead to neurological impairment, the risk of which is particularly high if the brainstem is affected. In case of repetitive hemorrhages causing a progressive neurological deficit, surgical treatment is therefore well established and seems justified. Whilst the main treatment for CCMs remains surgery, radiotherapy is also established. The aim of radiosurgery is to lower the risk of hemorrhage without taking the risks of a surgical procedure; the results are discussed controversially. Medical therapy is currently under investigation. Potential drug candidates include beta-blockers, statins, and anticoagulants¹⁴.

Operative risks and morbidity

CCMs

Every type of brain surgery carries certain general risks, mainly infection of the surgical site, secondary intracranial bleeding, and stroke. These risks, which of course also apply to the surgical treatment of VMs, are of fundamental nature and can be generally classified as relatively low. The specific risks of a CCM resection mainly depend on the location of the lesion. The more important the region (e.g. brainstem, areas of speech), the more severe the consequences in case of potential complications. The more vulnerable the region (many important structures located in a small area, e.g. brainstem), the more likely become potential complications. Furthermore, some areas of the brain are part of larger networks that can better compensate for potential damage, whereas in others, injuries are likely to result in a permanent neurological dysfunction. In general, the risk of a CCM resection is quite variable and should therefore be elucidated individually by the surgeon planning to perform the surgery. Larger studies have reported a general risk of 5%-15% of a permanent deficit, depending on the location. When performing surgery in vulnerable areas, the patient should also be prepared for potential temporary neurological deficits. These occur more frequently (30%) but are typically resolved within 3-6 months after surgery. Resections of CCMs in less vulnerable regions present much lower risks of permanent or temporary neurological deficits. In many cases, patients 'only' suffer from the consequences of the microsurgical approach (local pain, healing process of soft tissue,

cosmetic impairment). Nowadays, many approaches are small and show optimal cosmetic results.

AVMs

These general principles also apply to AVMs. Furthermore, specific to AVMs, treatment risks can be estimated using special scales, e.g. the Spetzler-Martin grading. The higher the score, the higher the risks of potentially severe procedural complications. Main parameters of such scores are size, venous drainage, and location of the AVM⁷.

Other types of interventions (radiosurgery, embolisation) also carry procedural risks comparable to those of surgery, even though these risks are of a different nature, as a surgical opening of the skull is not necessary. Main subject of current research on VMs is the comparison of the different available treatment modalities.

Follow-up

No standard follow-up protocols for untreated AVMs and CCMs have been established yet. Most practitioners recommend MRI follow-ups on a yearly (or 2-3 years) basis. For AVMs, repetitive DSAs may be necessary to rule out associated aneurysms and venous varices.

Pregnancy

The bleeding risk of CCMs does not appear to be increased during pregnancy and puerperium, and vaginal delivery seems safe.

In contrast, recent studies have demonstrated an increased bleeding risk (3-fold) for AVMs during pregnancy and puerperium^{15, 16}.

References

1. Secca MF, Vilela P, Ferreira JL, Lopes FC, Goulao A. Endovascular Pressure Measurements: Validation with a Pulsatile Flow Model and Haemodynamic Assessment of Brain AVMs. *Interv Neuroradiol* 2004;10:281-291.
2. Berman MF, Sciacca RR, Pile-Spellman J, et al. The epidemiology of brain arteriovenous malformations. *Neurosurgery* 2000;47:389-396; discussion 397.
3. Richter T, Nestler-Parr S, Babela R, et al. Rare Disease Terminology and Definitions-A Systematic Global Review: Report of the ISPOR Rare Disease Special Interest Group. *Value Health* 2015;18:906-914.
4. Flemming KD. Incidence, Prevalence, and Clinical Presentation of Cerebral Cavernous Malformations. *Methods Mol Biol* 2020;2152:27-33.
5. Halim AX, Johnston SC, Singh V, et al. Longitudinal risk of intracranial hemorrhage in patients with arteriovenous malformation of the brain within a defined population. *Stroke* 2004;35:1697-1702.
6. Horne MA, Flemming KD, Su IC, et al. Clinical course of untreated cerebral cavernous malformations: a meta-analysis of individual patient data. *Lancet Neurol* 2016;15:166-173.
7. Chen CJ, Ding D, Derdeyn CP, et al. Brain arteriovenous malformations: A review of natural history, pathobiology, and interventions. *Neurology* 2020;95:917-927.
8. van Beijnum J, Lovelock CE, Cordonnier C, et al. Outcome after spontaneous and arteriovenous malformation-related intracerebral haemorrhage: population-based studies. *Brain* 2009;132:537-543.
9. Al-Shahi Salman R, Hall JM, Horne MA, et al. Untreated clinical course of cerebral cavernous malformations: a prospective, population-based cohort study. *Lancet Neurol*

Familial disease

In AVMs, a familial disease is an absolute exception - most cases are sporadic. In contrast, up to 20% of CCM cases are familial.

Familial cases are characterised by multiple lesions and follow an autosomal-dominant pattern of inheritance. If a familial disease is suspected, genetic counseling should be initiated¹⁷. Patients with Osler-Rendu-Weber Syndrome have increased risk to have an AVM.

Summary

In summary, CCMs present a common finding. With the increasing utilisation of MRI for 'screening' purposes, incidental discoveries of CCMs are likely to increase even further. Many patients harboring a CCM will never face any or any severe symptoms. In these patients, the lesion can be monitored or even neglected. In some patients, however, recurrent bleedings of the lesion or epilepsy may render a treatment necessary, normally consisting of a surgical resection. Familial disease is common and genetic counseling is recommended in such cases. AVMs, on the other hand, are much less frequently diagnosed. The decision to treat or not to treat is more complex.

In addition, interventions tend to be more complex and hemorrhages are more dangerous, often leading to a fatal outcome in a significant proportion of patients. For both VMs, a dedicated interdisciplinary team with long-term experience in the field is a basic prerequisite for a successful treatment.



Priv.-Doz. Dr. med. P. Dammann

Specialist for neurosurgery and pediatric neurosurgery
Essen University Hospital
Essen (Germany)

○ Philipp.Dammann@uk-essen.de

2012;11:217-224.

10. Dammann P, Jabbarli R, Wittek P, et al. Solitary Sporadic Cerebral Cavernous Malformations: Risk Factors of First or Recurrent Symptomatic Hemorrhage and Associated Functional Impairment. *World Neurosurg* 2016;91:73-80.

11. Chen B, Herten A, Saban D, et al. Hemorrhage from cerebral cavernous malformations: The role of associated developmental venous anomalies. *Neurology* 2020;95:e89-e96.

12. Akers A, Al-Shahi Salman R, I AA, et al. Synopsis of Guidelines for the Clinical Management of Cerebral Cavernous Malformations: Consensus Recommendations Based on Systematic Literature Review by the Angioma Alliance Scientific Advisory Board Clinical Experts Panel. *Neurosurgery* 2017;80:665-680.

13. Dammann P, Wrede K, Jabbarli R, et al. Outcome after conservative management or surgical treatment for new-onset epilepsy in cerebral cavernous malformation. *J Neurosurg* 2017;126:1303-1311.

14. Polster SP, Cao Y, Carroll T, et al. Trial Readiness in Cavernous Angiomas With Symptomatic Hemorrhage (CASH). *Neurosurgery* 2019;84:954-964.

15. Joseph NK, Kumar S, Brown RD, Jr., Lanzino G, Flemming KD. Influence of Pregnancy on Hemorrhage Risk in Women With Cerebral and Spinal Cavernous Malformations. *Stroke* 2021;52:434-441.

16. Lee S, Kim Y, Navi BB, et al. Risk of intracranial hemorrhage associated with pregnancy in women with cerebral arteriovenous malformations. *J Neurointerv Surg* 2020.

17. Labauge P, Denier C, Bergametti F, Tournier-Lasserre E. Genetics of cavernous angiomas. *Lancet Neurol* 2007;6:237-244.

TESTIMONIAL Epilepsy due to multiple cerebral cavernomas

Anja R. (Federal Association of Congenital Vascular Malformations)

To start with, I am 36 years young and have multiple cerebral cavernomas that have been known since I was 19. In the summer of 2020, a cavernoma was partially surgically removed. Since then I have been without seizures.

A decisive turning point in my medical history was the diagnosis of epilepsy in 01/20. After an EEG, my neurologist diagnosed me with symptomatic epilepsy with focal episodes. He said he suspected that my left temporal cavernoma was the trigger.

At that time, I had already been having up to 20 seizures a day for more than 1.5 years.

They were always the same symptoms of varying intensity. They always started with a shivering feeling or tingling from the foot to the head, followed by goose bumps, some nausea with smell and taste disturbances, slight hyperventilation and slight heart racing. Sometimes they were accompanied by dizziness, anxiety or hot flushes. During a seizure, I could not follow conversations, felt absent for a short time and had word-finding difficulties. However, I was never unconscious. I also had epileptic seizures at night and therefore suffered from a chronic lack of sleep.

At first I was rather sceptical about the findings. Over the last few years, I have been to various doctors who have given me various suspected diagnoses and treated me, but without any improvement in my symptoms. Most recently, I was given drugs for antidepressants and sleeping pills because of the misdiagnosis of "panic attacks". I told all the doctors that I had multiple cerebral cavernomas. Later they told me that they didn't know this disease and that they never thought of epilepsy with the symptoms. The neurologist initially treated me with Lamotrigine and the number of my focal seizures steadily reduced. The diagnosis helped me to cope better with the symptoms. I finally had an explanation for myself and my social surroundings.

With the question of an indication for surgery, the neurologist recommended that I visit the neurosurgery department in 04/20 with current MRI images. The neurosurgeon considered surgery necessary and explained to me that the disease can lead to neurological deficits, but also to death. She advised me against a timely operation because of the current corona pandemic, as infection would be life-threatening. She pointed out to me that there was no epilepsy centre in the area for more detailed clarification and that she had not yet removed a cavernoma, but would be confident enough to do so. This conversation made me feel very insecure, so I decided to look for suitable help myself.

Due to the misdiagnosis of 'panic attacks', I had sought a therapist on my own. He now helped me to deal with the ill-

ness and to make decisions about further therapy. I had a great need for exchange, information and counselling, as there was no one in my area who knew anything about this vascular

malformation. I discovered the 'Federal Association for Congenital Vascular Malformations' on the internet. Both the members of the association and the associated website **kavernom.de** gave me good information. I got information about which clinics, specialised neurosurgeons and contact persons there are. I chose three neurosurgeons in my neighbourhood and got advice from all of them. I wanted to be proactive in order to make the best decision for me and my family. My most urgent question was whether the cavernoma on the left temporal side was responsible for my epilepsy and whether surgery was advisable. The urgency increased because despite changing the medication to Levetiracetam (highest dosage), freedom from seizures could not be established. In all three clinics, the neurosurgeons saw a clear indication for surgery.

I decided to go to Greifswald University Hospital. There were various decision criteria for me. The decisive factor for me was the trusting consultation with the neurosurgeon Prof. H. Schroeder. He answered my questions promptly even after the consultation. He has performed many successful brain operations and also specialises in the treatment of cavernomas. In addition, he asked me for a quick surgery scheduled for the summer, as the chances of subsequent freedom from seizures would be greater if there was no further bleeding. It also seemed uncertain to me whether an operation would be possible in the autumn due to the corona situation. Other reasons for me to choose the clinic were that it was possible to have a check-up in the epilepsy centre, that my parents and my brother lived nearby and could support me, and that a genetic test was also possible. There was a presumption of familial cavernomatosis, as both my father and his sisters have multiple cerebral cavernomas. I have a five-year-old son and wanted long-term medical care. It was a relief for me when it was certain that I would be operated in Greifswald in July 2020. I had done everything I could to make a good decision for myself and my family. I had to leave the rest to the medical staff.

Recently, I found out that it is indeed a genetic disease. What I will do with this information, I do not know yet...



Photo: Anja R.

TESTIMONIAL Wilma Westenberg (26) with Facial Infiltrating Lipomatosis (FIL)

Brenda Kluijver (HEVAS)

Wilma was born with a swollen cheek. For years, she and her parents searched for answers. In 2017 she obtained a second opinion and was diagnosed with FIL. Now Wilma knows she is not the only one, and travels around the world to meet others with FIL.

'Until recently, doctors didn't know what I had,' Wilma begins. 'We only knew that the tissue consisted of lipoma and lymphangioma'.

Wilma underwent two surgeries when she was nine months and 2.5 years old. Unfortunately without success. After both surgeries, everything grew back immediately. Wilma's jaw, teeth and bones also grow differently. For this she has undergone surgery in 2006 and 2020 and more surgeries will be needed in the future. Unfortunately nerves were damaged during surgery, causing Wilma to have little feeling in her lower lip.

When she was 12, Wilma started a website about her life and condition. She won several prizes and was invited to give a TED talk when she was 18.

'I sometimes received messages through my website. People advised me to go see the Hecovan Expertise centre in Nijmegen'.

When Wilma wanted to know more about the heredity of her condition, she decided to get a second opinion in Nijmegen. Here they immediately suspected that it could be a PIK3CA Related Overgrowth condition (PROS).

'They searched into literature and called me a few weeks later with life changing news: they found a diagnosis! Facial Infiltrating Lipomatosis, which is one of the conditions caused by a PIK3CA mutation. They had never heard of FIL before and didn't know anyone else.'



Wilma traveling...

Photo: Wilma Westenberg

'I travel around the world to meet others with the same condition.'



Wilma (pictured above) at a meeting in San Diego

Photo: Wilma Westenberg

After getting diagnosed Wilma began searching for others. It has become her life goal to visit as many people with FIL as possible.

By now she knows more than 60 people all over the world. 'For the past 3 years I have visited 15 people with FIL, who I call my extended family, in the USA, Brazil and Europe. This year I was supposed to go to Canada, Russia and Europe, but unfortunately this was all postponed because of Corona. I have a long list of trips to make in the coming years!'


Editorial's note:

For more information visit Wilma's website:

wilmawestenberg.nl

Please scan

Website



Generated with www.qrcode-monkey.com

TESTIMONIAL Conchita Anaktototij (32) has microcystic lymphatic malformation

Brenda Kluijver (HEVAS)

From countless surgeries to injections and wearing an elastic face mask: Conchita Anaktototij has not yet had a treatment with the results she hoped for. One time she ended up in an artificial coma due to complications. She remains hopeful and is open to anything.

‘Doctors told my mother that I would probably die soon after I was born,’ Conchita says.

‘They had no idea what condition I had: a large swelling in my neck and cheek, but also a hemangioma on my tongue.’

Her first two years consisted mostly of uncertainty and examinations. Many surgeries followed. At a certain point there were no options left. I then started searching online for options because I couldn’t believe it.

About six years ago, her online search led her to a study with the drug OK432, which was mainly used for immunotherapy of cancer and lymphatic malformations. The first two injections did nothing; the third had a dramatic effect. ‘I reacted to it so badly; my whole throat swelled up and I couldn’t breathe. I was given a cannula to breathe through and was kept in an artificial coma for a week and a half,’ Conchita says. ‘When they woke me up, I mentally broke down. I couldn’t remember anything and found the idea of a cannula hard to deal with. I had to learn everything all over again and spent months rehabilitating.’

Conchita sought out a second opinion in Nijmegen and was diagnosed with microcystic lymphatic malformation.

‘I keep dreaming of a more normal appearance’.



Photos: Conchita Anaktototij

‘This diagnosis and new developments gave me two more treatment options to try.’ And so Conchita began Bleomycin injections. It didn’t do much.’

‘A disappointment, but I then hoped for good results with Sirolimus. Unfortunately, this drug didn’t show good results and I developed a white blood cell deficiency. I still hope that one day something will work.’

Hope shimmers behind the clouds of worry.

Tom Borg

TESTIMONIAL Chloe's story (CMTC)

Sarah Gross (CMTC-OVM)

Chloe was born in June of 2012. The next day, we noticed that her right arm was purple, but we dismissed it thinking that her hospital bracelet was on too tight, or possibly even that she was just very cold. The purple marbling persisted through our entire hospital stay (5 days because I had a C-section) and was still present even after we had gotten home. I kept a close eye on it, but with everything else that comes with a brand new baby, I somewhat just pushed it to the back of my mind and hoped it would go away.

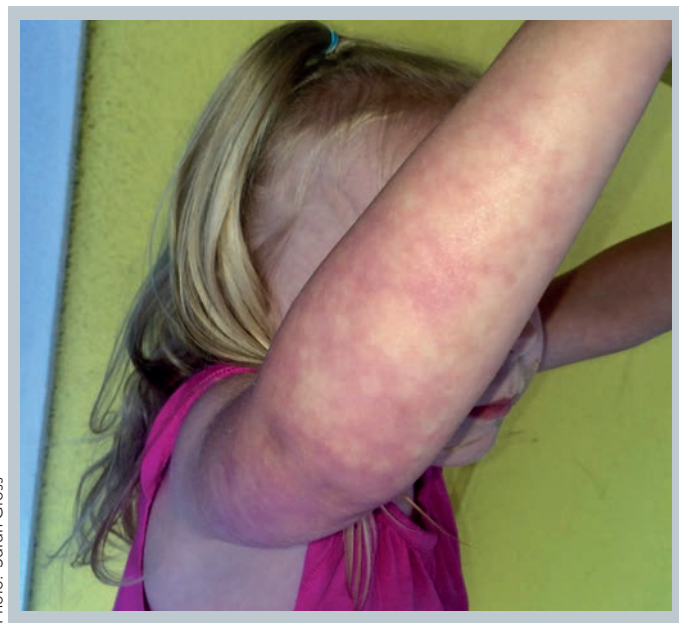

Photo: Sarah Gross

Her arm would get darker when she was cold or when she was sick or even mad (we joked that it was her mood arm). One evening after her bath when Chloe was about 6 months old, I was playing with her and I noticed that it looked like her right hand was a little swollen. I compared it to her left hand and saw there was a distinct difference in size.

☰ This was when I panicked.

We took her to her paediatrician the next week to have her seen. The paediatrician was just as puzzled as we were about the purple marbling and size difference - he suggested it could be a hemangioma or a port-wine stain. But, just to be sure, he referred us to the Medical Vascular Center. Again, the doctors were just as puzzled as our paediatrician was. They did x-rays and an ultrasound on her arm and hand, and then they brought in a team of doctors and medical students to take pictures. They had never seen a presentation quite like hers, and we were left with very little answers. I was very frustrated and worried about what could be going on with my daughter's arm. I came home and immediately started doing my own research on what could be causing the coloration and size difference.

☰ After many, many days of researching, I came across an article about a vascular condition called CMTC.

Everything sounded familiar - the marbled purple appearance of her skin, the girth difference in her arms and the fact that her arm would change colours based on her temperature or if she was not feeling well. I was immediately relieved because I finally felt like I could possibly have a name for her condition. After I found out this information, I was able to call our paediatrician and get a referral to a doctor at Dallas Children's Hospital to get a CMTC confirmation and to make sure that she did not have any other underlying issues that go along with that diagnosis. She ended up getting a full-body MRI and more x rays, and the doctor was able to confirm that she did, in fact, have CMTC (Cutis Marmorata Telangiectatica Congenita).

He was also able to tell us that the MRI showed no additional problems and for us to just keep an eye on the size discrepancy in her hands. After having a firm diagnosis, I found that there was a CMTC support group on Facebook. I cannot tell you how relieved I was to see that there were other people going



We have used this service for this magazine and say thank you.

Free for commercial usage

All generated QR Codes are 100% free and can be used for whatever you want. This includes all commercial purposes.

○ www.qrcode-monkey.com



through what I was and to see pictures of other children with markings similar to Chloe's.

It literally took the weight of the world off my shoulders.

After joining the CMTC-OVM Facebook page and making contacts with some of the other members of the page, we decided we would go to the Dutch CMTC-OVM conference in St. Louis, Missouri. Chloe was 1 year old by this time, and we took her and had her seen by Dutch Prof. Dr. Maurice van Steensel. It was at this time that he told us that he felt she was closer to a diagnosis of Klippel Trenaunay Syndrome because of the size of her affected arm and hand (being larger than the other), but that her markings appeared to be in line with CMTC. He officially diagnosed her as having KT with other vascular malformations.

We learned so much at the conference and were able to meet other parents and children with CMTC and other vascular anomalies, and our hearts were uplifted with the support and diagnosis we received.

Chloe is 6 years old now and is perfectly happy and healthy. She plays soccer and has taken dance classes for 5 years, is one of the top readers in her class, and loves to play outside and work in the garden with us. Her markings are still there, and they do still get darker when she is cold or sick (and even when her mood changes), and her hand is still larger than the other one. She does have some pain, especially when writing or coloring for long periods of time, but it is never anything that is too extreme or



Photo: Sarah Gross

bothers her too much. She does tend to bruise and sunburn easier on her affected arm, and we do not allow any blood pressure cuffs or pokes or sticks from shots in her right arm just in case of clotting issues.

I really cannot put into words what it has meant for us to be a member of the Dutch global CMTC-OVM family. To be so scared because you do not know what is wrong with your child, but then be able to find a family that understands and is able to calm your fears has been truly spectacular.

For more information visit our website:
www.cmtc.nl/en/chloes-story-usa/

k kreativ & sozial
 Agentur für Medien-Design



Creative advertising for social causes.
 Professional, personal and fair.

You serve people, I present to the outside world how well you do it.
 From concept to layout to implementation. Vast experience in magazines.
 Across national borders. Communication in English (only e-mail) or in German.

www.creative-and-social.eu

Photo: Kathrin Sachse

TESTIMONIAL Marion (35) with Klippel Trenaunay Syndrome (KTS)

Brenda Kluijver (HEVAS)

Marion has KTS, a rare disorder with port wine stains (capillary malformations), venous and/or lymphatic malformations and over- or undergrowth of bone and soft tissue. Until recently, Marion thought she had a mild form, but it turned out to be life threatening. Twice.

'I'm lucky that I don't have excessive overgrowth of bone or soft tissue and can move well and pain-free. I do spinning at the gym and cycle twenty kilometers to and from work, which is wonderful,' she laughs.

Excess vessels and pregnancy complications

'During my pregnancy I found out that I actually didn't have such a mild form as I always thought. At the twenty-week ultrasound, my uterine wall was 6 instead of 2 centimeters. It was one big tangle of excess vessels.'

A C-section was impossible; it had to be a natural birth. Inside the sheath was a large collection of blood vessels. The vessels popped open during labor. 'I lost five litres of blood and almost didn't make it. I was told I cannot have any more children in the future.'

Pulmonary embolisms

Two years ago, another complication intruded on Marion, very slowly and viciously. 'KTS patients have an increased risk of thrombosis and pulmonary embolism. I had known that for years and I was aware of the symptoms. Yet for months I didn't realise this was going on in my body. About four months before the diagnosis of pulmonary embolism, I became short of



Photo: Marion

breath while cycling. Chatting with a colleague while cycling was no longer possible, and a few times during spin classes I got blue ankles. I literally had to gasp for breath. I couldn't sleep well, even though I was extremely tired. My heart raced and I was restless as soon as I laid down.' Later it turned out Marion had three pulmonary embolisms. 'I can't blame the lung specialist or my family doctor. I could still play sports, work, I wasn't overweight and I did not have any noticeable pain or red/swollen leg. I use anticoagulants twice a day for the rest of my life because the risk of recurrence is too great'

'I now always advise people with KTS to tell their family doctor or treating physician that there is an increased risk of thrombosis and pulmonary embolism. If there are any symptoms, this is what they should check first.'

Classification of Vascular Anomalies

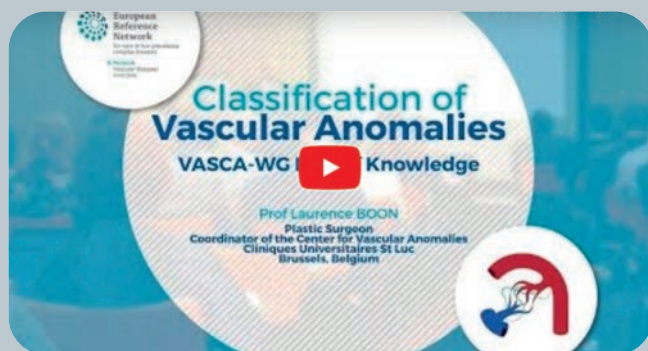


Photo: VASCERN

Diagnostics Approaches for Vascular Anomalies

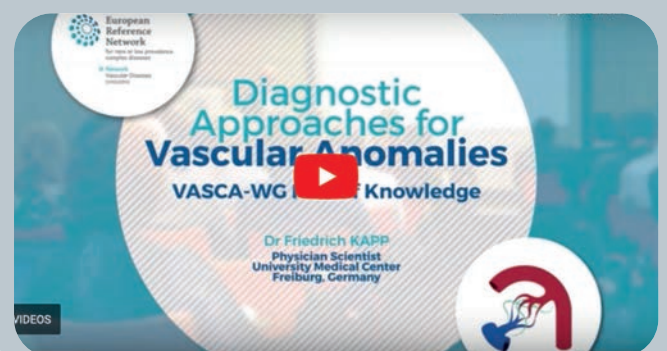


Photo: VASCERN

TESTIMONIAL Julia (9) has a hemangioma on her face

Brenda Kluijver (HEVAS)

When your child has a hemangioma on the face, a lot is coming your way. Mother Liselotte can relate. When Julia was born, there was a big bruise on her cheek. ‘The pediatrician first told us it was caused by engorgement. Later they told us it was a port-wine stain. There I was, feeling pride and grief at the same time.’

(Wrong) diagnoses

Liselotte: ‘Soon we found out that Julia’s right eye could no longer open. They thought it was an eye infection, but now we know that it was caused by the growing hemangioma. Later we received another wrong diagnosis: Sturge Weber’s Syndrome. A huge shock.’ Liselotte and her husband demanded a referral to a specialist. Finally, the correct diagnosis was made in just three seconds: a hemangioma. Later it turned out to be part of PHACE syndrome. They treated Julia with propranolol.

Lies: ‘The medication seemed to work quickly. On the first day she was given the drug, her eye opened after being closed for three months.’

Different appearance

Mother Liselotte: ‘Sometimes I feel the need to explain what she has, especially when people are looking. Seeing people stare is very painful.’

Julia: ‘It’s less visible now, back then it covered almost half of my face. Sometimes I don’t want to talk about it, sometimes I tell

‘You want her to know she is fantastic just the way she is, but there should also be room for sadness’

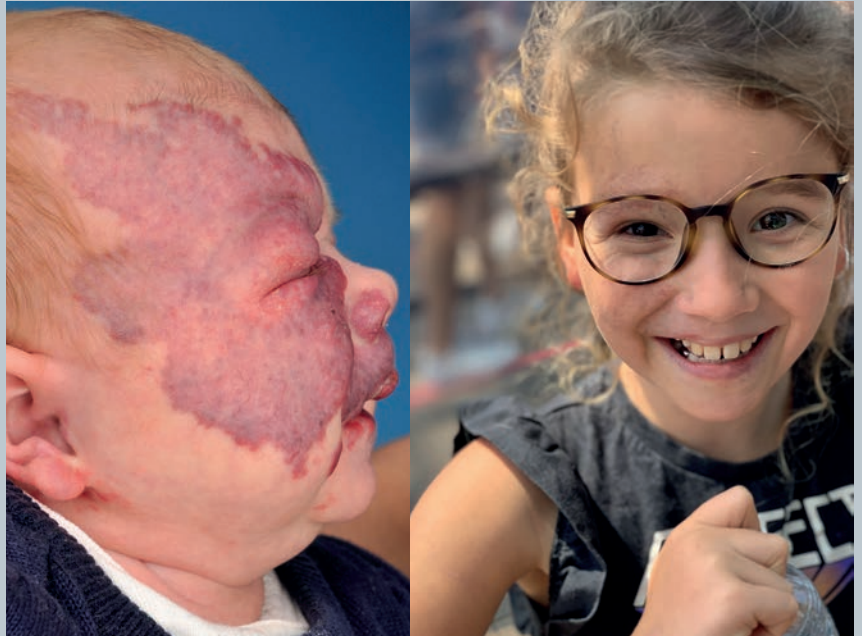

Photo: Liselotte

the whole story.’

Liselotte: ‘We live in a world in which appearance is important. We always tell Julia she’s good the way she is, and the inside is more important than the outside. At the same time, I want to support her in her wish.’

Julia recently started laser treatment to make the hemangioma less visible. For Liselotte, Julia with hemangioma is her beautiful Julia.

Pills of Knowledge (PoK) Video Playlist from the VASCA-WG on YouTube

Short video lessons (approximately 3-5 minutes in length) in which an expert speaks on a specific topic selected and validated by the Rare Disease Working Groups (RDWGs).

Please scan



Generated with www.qrcode-monkey.com

Multi-disciplinary Expertise Teams for Vascular Anomalies

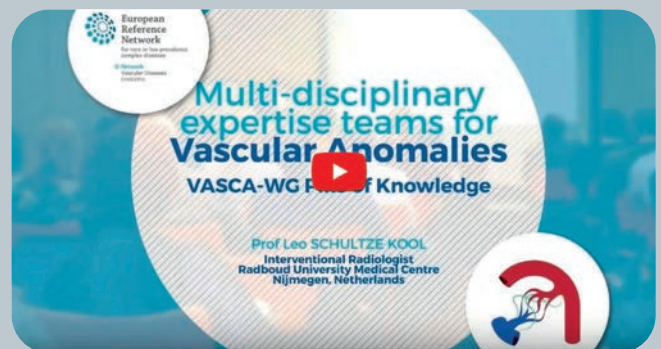

Photo: VASCERN

Clear and simple explanations of genetics of vascular malformations

D. Maroeska W.M. te Loo, MD, PhD, Pediatric Hematologist and Clinical Pharmacologist

Vascular malformations are present at birth although they are not always detected at that time point. They usually grow proportionally with the patient. The symptoms and discovery of the vascular malformations can occur at birth, later during childhood or even adulthood.

But why do these vascular malformations occur? The reason is that during pregnancy a genetic change, also described as a mutation or pathogenic variant, occurs in the DNA of the embryo. The genetic change, however, may not occur through the whole body but can, depending on the time point during embryogenesis, appear in one part of the body or be present at several locations (Figure 1).

The genetic alteration in the DNA of the child occurs spontaneously most of the time meaning that parents do not carry this mutation, although rare cases of families with vascular malformations have been described.

The fact that these mutations mostly develop spontaneously means that nothing can be done to prevent this. Furthermore, these mutations are not present in the germline and are thus not inherited (so called somatic mutations). In the rare cases of familial inheritance, a gene is inherited (= germline mutation) leading to an increased risk for development of vascular malformations. There is a large variability in the phenotype

observed with different severity of lesions and difference of age of onset, despite the same germline mutation present. The phenotype is depending, like in those with spontaneously occurring vascular malformations, of the time point this second mutation occurs.

DNA and genetic changes

DNA is the abbreviation for deoxyribonucleic acid and stands for the hereditary material in humans and almost all other organisms. Most DNA is located in the cell nucleus and located on the chromosomes (figure 2). The hereditary information is stored within these chromosomes and have a code made up of four chemical bases: **adenine (A), guanine (G), cytosine (C), and thymine (T)**. These bases form pairs and form together a double helix. The code, or the way the base pairs are arranged, has a function and encodes for example for the colour of eyes, growth factors but also proteins. The smallest change in this DNA can lead to a different function of the code. In the case of the development of vascular system, such a small alteration during embryogenesis can lead to the development of vascular malformations.

Genetic mutations and treatment

Since the discovery of the first somatic mutations in a vascular malformation of more than a decade ago, it became clear that

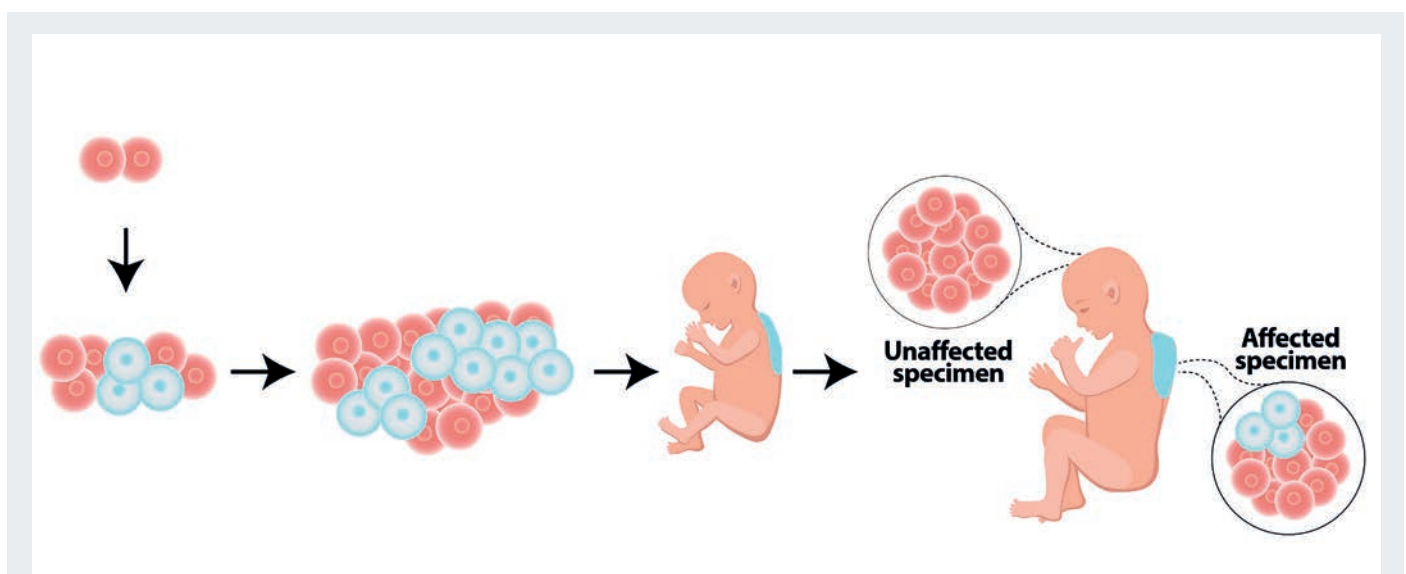


Figure 1: In the first seven weeks after conception, an embryo develops. Cells divide to form this embryo. During this process, somatic mutations (mutations not present in the germline) can occur leading to the development of vascular malformations, skin and bone abnormalities or even brain abnormalities.

there are different kind of mutations located in two major intracellular signalling pathways located in the cell.

These signalling pathways are like the roadmap for the function of a cell in which a group of molecules in the cell work together.

In the human body we have a lot of these signalling pathways but in the case of vascular malformations two seem extremely important. This are the RAS/MAPK/ERK and/or the phosphatidylinositol 3 kinase (PIK3)/protein kinase B/mammalian target of rapamycin (mTOR) pathway.

Within these pathways different kind of mutations can be found, leading to the appearance of vascular malformations. Mutations in the RAS/MAPK/ERK pathway can be found in those patients with arteriovenous malformations whereas mutations in the PIK3CA/mTOR pathway are more frequently observed in patients with venous/lymphatic malformations and patients with overgrowth syndrome (PROS syndrome).

Although these mutations occurring can be different, they have in common that they lead to hyperactivation of one of the pathways leading for example the growth of abnormal vascular vessels.

By knowing which pathway is activated, or which mutation is the cause of the activation, more targeted medical treatment can be given. For example, rapamycin or so called Sirolimus, is able to inhibit the mTOR pathway. Furthermore, for those patients harbouring a PIK3CA mutation, new agents like Alpelisib seem to be promising.

TESTIMONIAL Genetics

Astrid (VASCAPA)

My name is Astrid and I am 24 years old. I was diagnosed in 2017 with PTEN syndrome.

Prior to that, I had surgery 3 times in my life: at 8 months of hamartoma, at 11 years of an arteriovenous malformation and in 2016 of the thyroid.

The innovation in past years on genetic testing has helped advance research on rare diseases. In my case, it helped to diagnosed my PTEN syndrome, which was done after several analysis of my samples. The PTEN syndrome is a deformation/mutation of the PTEN gene. The PTEN gene is a tumor suppressor gene. When deformed, it can cause different symptoms in the patient and, among other things, a high risk of cancer. The types of cancer that are at risk are: breast, thyroid, kidney, endometrium, colon and melanoma. Another very high risk for a PTEN patient is to give birth to a child who would carry the same gene deformation.

So what has been the purpose of genetic testing in my case?

First of all, to check whether my parents had this deformation of the PTEN gene, and thus analyse if I inherited the syndrome from my family. Secondly, I was able to understand whether there was a risk that my future offspring could inherit this gene deformation.

It all depends on the disease you or a member of your family has. For the inherited diseases, the genetic testing allows to identify if a disease has been inherited, and even more, define if a family member that has no symptoms is still a carrier of the gene defect.

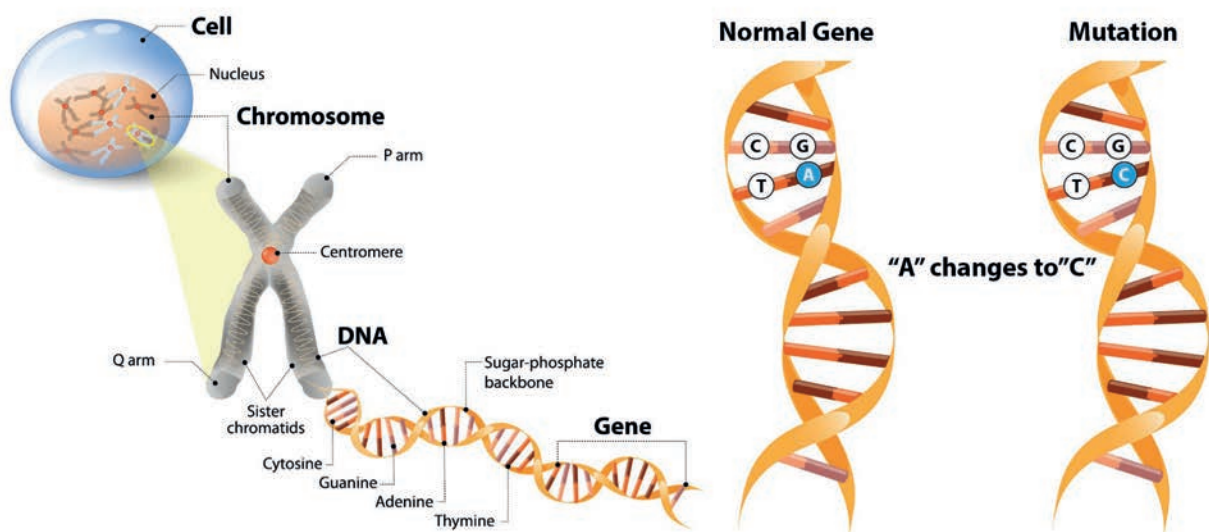


Figure 2: Schematic representation: in the cell you can find the nucleus. In the nucleus chromosomes are present. These chromosomes carry DNA. DNA forms a double helix due to the binding of base pairs. A single change in base pairs can lead to a functional change and is called mutation.

Importance of Scientific Research for Vascular Anomalies*

Interview with Prof. Miikka Vikkula by Maria Barea (VASCAPA)

What is genetic research and why is it important for rare diseases (and hence for vascular anomalies)?

Genetic research aims to identify defects in genes that are responsible for diseases. This is **most relevant to the study of rare diseases, of which 80% have a genetic origin.**

Establishing the specific genetic root-cause of a disease allows precise diagnosis and the development of targeted therapies.

Within the Human Molecular Genetics Group at the de Duve Institute, UCLouvain (Brussels-Belgium), the genetic causes of vascular anomalies are studied in order to understand their effects *in vitro* and *in vivo*, and be able to propose new treatments.

How to improve research effectiveness in the field of rare diseases?

The following elements are needed to be able to perform quality research:

- An accurate clinical diagnosis. It is therefore essential that general practitioners refer patients to multidisciplinary centers of expertise where experts can establish a precise diagnosis.
- Participation of patients who provide samples (blood, tissue or other).
- International databases (registries), where the phenotype - the set of observable traits - and genotype - the genetic mutation when it has been identified of the individual - of patients are listed. In order to link them and increase the amount of information available, these registers must be FAIR (easy to Find, Accessible, Interoperable and Reusable) as targeted by the European Reference Networks (ERN) (for more details, see article 'Chapter 1: Introduction - Registries for rare diseases' by Leo Schultze Kool on page 18).
- Research on an international scale, in particular for ultra-rare diseases (which affect 1 person in 50,000).
- National and international networking between laboratories, in order to combine the technical capabilities (equipment, reagents, etc.) and the know-how of two or even several laboratories. To achieve European-scale clinical trials, the ERNs link, among other tasks, the Reference Centers from the different countries.
- Tools implementing technological advances. In recent years research in the field of rare diseases has enormously progressed thanks to technological advances and the

introduction of software analysis, which have made possible to change the approach of genetic research and its results.

Why has genetic research advanced so fast in recent years?

Vocabulary: The DNA (DeoxyriboNucleic Acid) is made up of bases called: adenine [A], cytosine [C], guanine [G], and thymine [T].

In its most simple definition, a gene is a unit of heredity that defines a characteristic of an organism encoded in DNA.

The genome is the complete set of genetic instructions of such organism, also encoded in the DNA. The human genome contains 3 billion DNA base pairs: combinations of 'A-C-G-T'. Using sequencing methodology, the unique and specific order of these letters (ACGT) can be determined. In principle a genetic disease is caused by a mutation, a modified letter in the sequence. The following examples are meant to show what mutations are and do. These phrases' meaning changes when missing or misplacing letters:

- 'The employee asked the boss for a salary raise.' Is different than: 'The employee asked the boss for a salary race.'
- 'I brought you different desserts.' Is different than: 'I bought you different deserts.'
- 'You should brake your car if somebody is crossing the street.' Is different than: 'You should break your car if somebody is crossing the street.'

Initially, genetic research was done by the method of linkage analysis: a big family was studied to identify differences in the genetic markers between family members with or without the disease. The goal was to identify the region of the genome in which the mutated gene was located. But, consider that this is done over 3 billion pairs! This approach was very time-consuming and only worked for hereditary diseases and fairly large families. Thanks to this approach, the very first inherited genetic causes for vascular anomalies were identified: for example for hereditary haemorrhagic telangiectasia (HHT1) in 1994, and hereditary mucocutaneous venous malformations (VMCM) in 1996.

It is important to remember that a disease with a genetic cause does not mean that it is hereditary and in fact, many vascular anomalies are not hereditary.



Photo: CUSL / Hugues Depasse

Prof. Miikka Vikkula
Chair of the VASCA Working Group

In 2003 the entire human genome was sequenced for the first time, thanks to the international scientific research project known as the Human Genome Project, thus establishing a human reference genome. Geneticists discovered that a relatively small part of the genome, known as the exome, contains the bits of the genes that are used to build proteins.

already identified genes are now in routine clinical testing, and thus available to all patients. Yet, there is **still about 20% of patients affected by vascular anomalies for whom there is not yet an identified gene**. Therefore, scientists have also started to take a broader look: looking at the genome. In some cases, a third layer called the RNA (RiboNucleic Acid) is studied. RNA is the molecule that allows DNA to be translated into a protein. The machinery in our cells first transcribes the two DNA-based genes into numerous copies of RNA when needed, and then the RNA is read to build the needed protein. RNA can also be studied and sequenced like DNA, but its study may allow us to identify other possible causes for rare diseases.

Why are in-vitro and in-vivo models necessary for applied research?

Once a genetic mutation has been identified as root-cause for a specific disease or anomaly, the next step is to understand what the mutation does in the functioning of human cells. This is why an in-vitro model is first created: experiments are carried out on cultured cells, not on an individual's body. In this way, researchers can study, for example, the growth and the speed and orientation of movement, morphology of cells and what genes they express. Researchers try to leverage this in-vitro modelling more and more, trying even to create in-vitro organs. But eventually, in order to obtain information closer to the human being, it is necessary to generate a model of the disease in a living organism, such as an animal; these are called in-vivo experiments. They make possible to study the evolution of the disease, the effects of possible drugs and also the toxicology of a promising drug before testing it on humans.

Although the exome represents only 1-2% of the whole genome, it is considered that through its study we could identify 85% of the mutations that cause genetic diseases.

Nowadays, the sequencing of the entire exome is the most commonly used technique. It allows direct comparison of the patient's DNA with the reference, or DNA from the vascular lesion to the DNA from blood of the same patient, and it has completely changed the way we study rare diseases. But it is still very difficult to find the mutation that causes a disease, because between the exomes of different individuals there are still, in addition to errors, 20,000 to 60,000 differences that make us all unique. Hence the importance of studying it and sequencing it in order to understand the cause of many rare diseases.

How much do we know about vascular anomalies' genetic mutations?

For some vascular anomalies, researchers have been able to identify the responsible genetic mutation via traditional sequencing technologies (as there was an inherited familial mutation). For other individuals, we have found that the mutation is not present in blood cells but only in the cells of the specifically affected tissue by the vascular anomaly. This is what is referred to as a somatic mutation, and it could be identified in the exome. With this, researchers think that it could be **possible to have a genetic diagnosis for 60-70% of patients** affected by vascular anomalies. Most of the




Photo: LGD Alliance - Fotolia_112394567

In the field of vascular anomalies, the zebrafish and the mice have allowed us to understand the development of these anomalies and to test the efficacy of potential drugs. The zebrafish is very helpful as it is a small fish that multiplies rapidly and is transparent when young, so researchers can see the vascular system through basic observation. The mice (a mammal) allows to study the disease much closer: scientists can try to recreate the disease by introducing genetic changes or cells found in patients. They can then fully study the pathophysiology of the disease and specially how to stop its development.

These two steps (*in-vitro* and *in-vivo*) are essential before we can begin a clinical trial with drugs in humans and only both combined can produce results that alleviate or end the immense suffering of the patients affected by vascular anomalies.

When and how are clinical studies for treatments performed?

Researchers and doctors can only start clinical trials with humans after verifying the promising effects of a molecule (a drug) based on the results of the effects and toxicology in the *in-vitro* and *in-vivo* tests. The clinical trial is conducted in 4 stages, each of which aims to study one aspect of the drug and/ or its effects on the disease.

- **Phase I** aims to assess the toxicology at low scale.
- **Phase II** aims to assess the efficacy of the drug on the disease.
- **Phase III** is for testing (on a bigger scale) the efficacy and dose of the drug using the Outcome measures (what are we going to measure, see article "The OVAMA project" by Max Lokhorst on page 64), as well as possible adverse reactions.
- **Phase IV** focuses on the long-term follow-up, and discovery of adverse reactions.

Clinical trials present great challenges for rare diseases, as the number of patients is limited by the very rare nature of the diseases and the development of drugs is generally focused on more frequent diseases.

Drug conversion or repurposing represents an additional option for treating rare diseases, and fortunately this is the case for vascular anomalies. There are molecules that have been developed for treating other diseases (mainly for cancer) that work on the same genetic pathways that have been identified as the causes for some vascular anomalies. Hence the possibility to repurpose them.

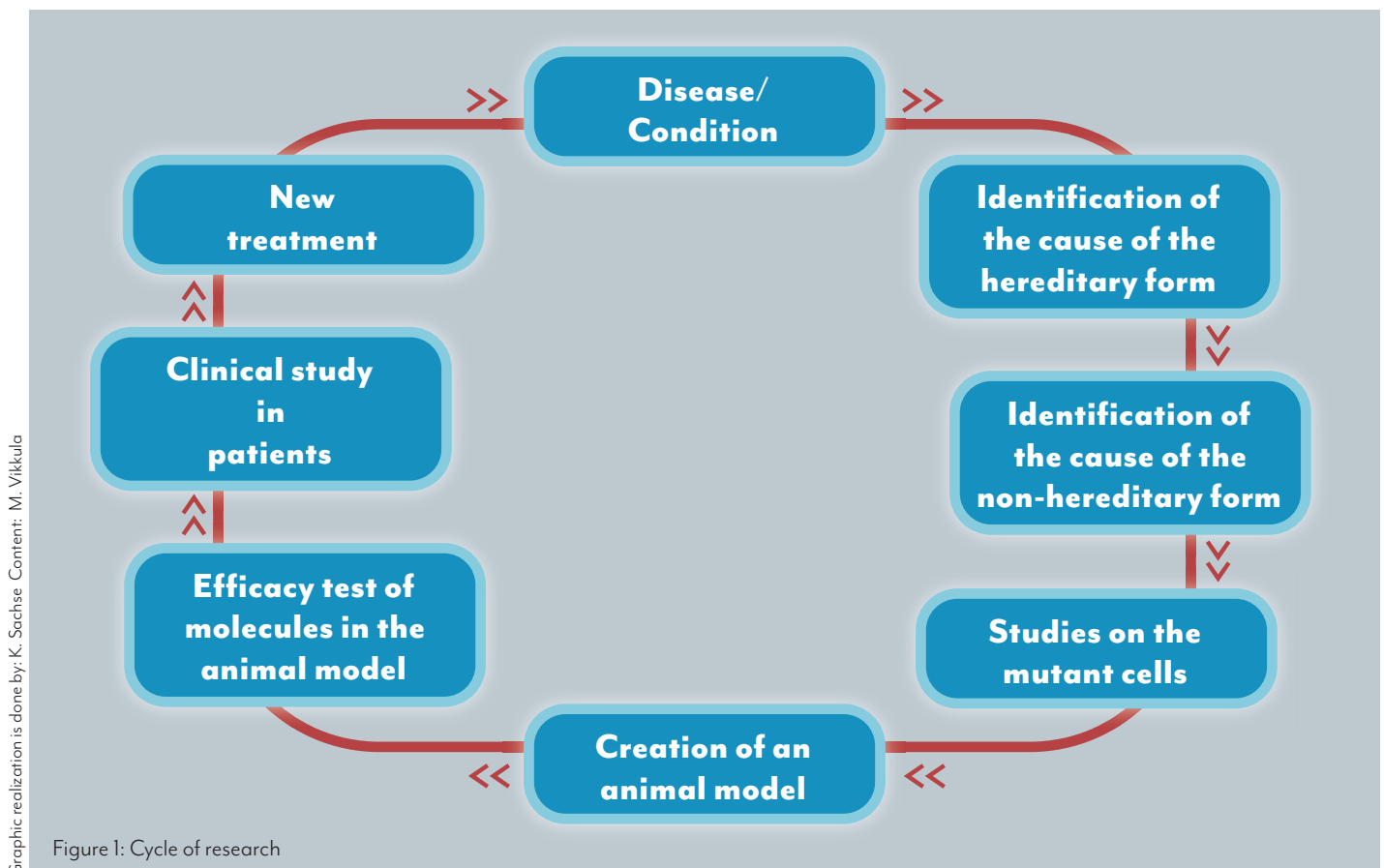


Figure 1: Cycle of research

How did the Research cycle allowed to identify a repurposed treatment for venous malformations?

This resulted from the **complementary work of fundamental research from our Genetic group at de Duve Institute and the clinical applied research from the Center for Vascular Anomalies** from Saint Luc University Hospital (Brussels).

See figure 1 showing the different steps in the cycle of research.

1. Disease/Condition: Venous Malformation (VM)
2. Identification of the cause of the hereditary form: in 1996 and using the Linkage analysis we identified the genetic mutation causing a hereditary form of venous malformation.
3. Identification of the cause of the non-hereditary form: Some 15 years later we identified a somatic mutation specifically in the malformation's cells; by analysing biopsy tissue samples from venous malformations and using modern 'Next Generation Sequencing' (NGS) techniques. This explained why only some veins were affected in the body of a patient: only the cells with the somatic mutation would develop the disease.
4. Studies on the mutant cells: Via In-vitro analysis we studied the cells affected by the genetic mutation, their signaling activation pathways and their effects on the maturation and stability of veins. We were able to identify an over-activation of a specific signaling cascade involving the mTOR protein.
5. Creation of an animal model: We developed then, with collaborators in Boston, USA, an in vivo analysis with a mouse model to mimic the human venous malformations and explore potential medications.
6. Efficacy test of molecules in the animal model: Rapamycin (known as Sirolimus and used to prevent organ rejection on transplants) had already been identified as inhibitor of the mTOR pathway. When tested in the mouse model it showed promising results, stopping the growth of the malformations.
7. Clinical study in patients: Moving to clinical trials was simpler as it was to repurpose of an existing drug. In small-scale clinical trials (phases 2A and 2B), Rapamycin showed a dramatic improvement on patient's symptoms and quality of life, especially in reduction of pain (a common symptom of venous malformation that can sometimes be daily and disabling). The group of Prof. Laurence Boon from the Center for Vascular Malformations, is now conducting a phase 3 clinical European study (250 patients) called 'VASE' (Vascular Anomalies Sirolimus-Europe), to assess the efficacy of this drug.

8. New treatment: Rapamycin for venous malformations shows how the proper understanding of a disease through genetic research leads to an effective treatment. Until now, venous malformations could only be treated by laser therapy, sclerotherapy and/or surgery. These treatments generally left scars, and were in some cases ineffective or not advisable, depending on the characteristics of the malformation.

The new Rapamycin treatment tackles the disease at its origin, preventing its development and translating in a significantly better quality of life for patients.

As Conclusion

Genetics and technology have finally given us a promising future for the development of targeted therapies for vascular anomalies. It is important to continue this research that can literally change the lives of patients. A similar evolution is possible for other rare diseases. It is therefore essential to develop long-term funding to allow research groups to consolidate and continue their momentum.

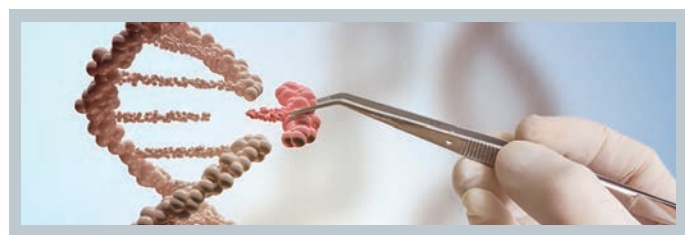



Photo: Fotolia_141880562

* Editorial's note:

A shorter version of this article focused on rare diseases, was initially published in the Quarterly magazine from « Ligue des Usagers de Santé » (LUSS)-Belgium, Le Chaînon, n°52, September 2020. In this issue, it has been further developed for vascular anomalies.

Prof. Miikka VIKKULA

MD, PhD, Geneticist, Head of the Laboratory of Human Molecular Genetics, Institut de Duve, UCLouvain. Member of the Board of Directors of Institut de Duve, UCLouvain. Member of the Royal Academy of Medicine of Belgium. Chair of the VASCA Working Group (Group for Vascular anomalies in VASCERN).



Generated with www.qrcode-monkey.com

V.A. Cure Project

Project Consortium & Mina Todorovic *

A multidisciplinary approach towards sustainable improvement in rare diseases care uniting Europe's top class vascular research to find new treatment strategies for vascular anomalies

V.A. Cure project is supported by Horizon 2020 - Marie Skłodowska-Curie actions. This European Training Network programme aims to enhance innovation, research and collaboration between scientific institutions and industry across Europe. Furthermore, the programme supports development of research skills among young scientists who will become the leaders of tomorrow in various scientific fields, including vascular biology.

V.A. Cure project members

This project unites seven academic leaders in the field of vascular biology: de Duve Institute (Belgium), Karolinska Institute (Sweden), Uppsala University (Sweden), Max-Planck Institute for Heart and Lung Research (Germany), Oulu University (Finland), Institut national de la santé et de la recherche médicale (France), University of Potsdam (Germany).



Seven academic groups are closely collaborating with a pharmaceutical company **AstraZeneca**, and a Finnish start-up company for organ-on-chip **Finnadvance**, both of which also host PhD students. In addition, five other companies including **Sysmex**, **Perimed**, **LLS Rowiak**, **Bayer** and **Navinci Diagnostics** provide expertise in the latest cutting-edge technologies in biomedical research. Furthermore, important project partners are the **Centre for Vascular Anomalies, University clinics Saint-Luc (CUSL)**, UCLouvain, Brussels, Belgium, internationally renowned multidisciplinary centre for the care of vascular anomalies, as well as the patient organisation **VASCAPA**.

Fourteen early stage researchers (ESRs) have been recruited, and are being supervised and trained by all the academic groups with AstraZeneca and Finnadvance.

This strong multidisciplinary, international and intersectoral collaboration enables important further discoveries in the field of vascular anomalies and brings us one step closer to finding treatments for this group of diseases.



Logos courtesy of the owners.

V.A. Cure project specific goals

- Delivering novel therapeutic targets and molecules to treat diseases related to vascular malformations and dysfunction.
- Providing a unique intersectoral doctoral training program for young researchers in vascular biomedicine with the insight into industries and biotechnology.
- Further education of PhD students in all skills necessary to build future leaders (communication, ethics, outreach, management).





Our multidisciplinary research programme is uniquely positioned to deliver novel therapeutic targets and molecules for the modulation of core signalling pathways implicated in vascular anomalies.

Furthermore, investigation of naturally occurring VA-causing mutations is a particularly powerful approach to unravel novel pathways that are crucial for normal vascular morphogenesis and function. Thus, our network may also not only provide new therapeutic targets for relatively rare VAs, but also for cancer, diabetes and cardiovascular diseases, in which dysfunctional vasculature is a hallmark.

V.A. Cure project aims to cover the whole innovation chain, from patient to bench and back to the patient. It holds overarching expertise in the three main signalling pathways involved in the development of the vasculature (TIE2-PI3K-AKT-mTOR-FOXO, BMP9/10-ENG/ALK1-SMAD and EPHB4-RAS-MAPK) and has state-of-the-art technologies needed for the in-depth study of vascular anomalies.

In this programme, fourteen young researchers are exposed to intellectually stimulating research and intersectoral environments, intensive training programmes, supervision from top-notch experts in the field and have a unique opportunity to collaborate with leading biotech and pharma companies - a cornerstone for development of new therapies.

Why is this research relevant today?

Scientific and technological advances today make it possible to answer questions that we could only dream of answering in the past. For instance, discovering genetic causes in heterogeneous samples, such as mosaic VAs, has become feasible with next generation sequencing (NGS).

To investigate effects of mutations, the new genome editing tools, such as CRISPR/Cas9, together with induced pluripotent stem cell (iPSC) technologies, facilitate generation of novel in vitro and in vivo models for vascular biology.

Inducible tissue-specific mouse models in combination with

use of high-end, label free and recently emerged imaging technologies allow generating accurate models for VAs, and image lesion development and therapy responses at real time at cellular and even molecular level.

In addition, the coordinator's group made a seminal discovery about 10 years ago demonstrating that sporadically occurring venous malformations (VMs) are the result of somatic genetic mutations.

This opened a new era of 'somatic genetic discovery using high-coverage targeted NGS' in developmental disorders, and has since yielded numerous important discoveries. Furthermore, the group has since shown that the somatic endothelial TIE2 mutations perturb the function of mTOR, which regulates growth, proliferation and differentiation. With Dr. Boon, Coordinator of the Centre for Vascular Anomalies, CUSL, the mTOR inhibitor **Rapamycin**, typically used to prevent post-transplant organ rejection, was tested to treat VMs. The drug yielded a great improvement in the quality of life in most patients in the clinical pilot study (n=20), and the group set-up in 2015 a larger, international, prospective, multicentric, phase 3 clinical trial (VASE). This is the world's first precision therapy for a vascular anomaly. Similarly, antiangiogenic agents, such as **Thalidomide** and **Avastin**, seem effective in patients with hereditary haemorrhagic telangiectasia (HHT). These developments prove that the severely handicapping vascular anomalies can be treated with drug therapies, and that discovery of novel therapeutics can be accelerated.

Members of the V.A. Cure network also uncovered essential signalling mechanisms downstream of TIE2 and other vascular anomaly-causing molecules. For instance, Max-Planck Institute (MPI) provided fundamental insight into the role of FOXO transcription factors in the endothelium, which function as critical downstream effectors of the TIE2-PI3K-AKT signalling axis. MPI demonstrated that FOXO1 is an essential transcriptional driver of vascular quiescence whose inactivation results in chaotic endothelial overgrowth.

V.A. Cure project objectives

- To identify the genetic causes of multiple vascular anomalies,
- To understand the molecular and cellular mechanisms disturbed by the mutations using in vitro models,
- To validate and further explore the pathophysiological mechanisms using in vivo models,
- To identify and test potential molecular therapies and targeting systems for VAs.

For this purpose, four scientific packages were created, and each ESR has a crucial role in working on one of the defined objectives (Figure 1, next page).

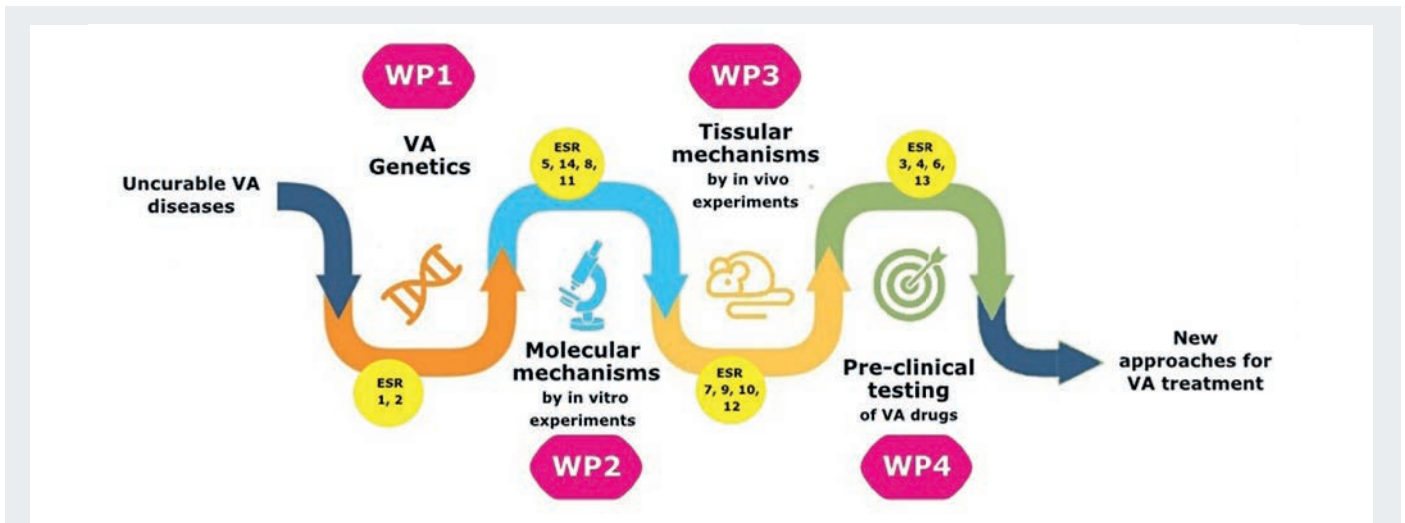


Figure 1: Objectives of the V.A. Cure project

V.A.Cure training programme for ESRs consists of a PhD programme, individual research projects, series of workshops, lectures and training provided on annual network meetings, international multidisciplinary and intersectoral collaborations and secondments (Figure 2).

Each student will have a secondment in other academic groups and/or a company that is relevant for his/her research. Thus, all students will gain knowledge from both worlds. Students are also involved in an intensive outreach programme in which they attend events, present their research to various audiences, attend top quality international conferences and at the end of the project organise **V.A. Cure Conference** in which results of this project will be presented to other scientists and the public.

V.A. Cure’s multidisciplinary and inter-sectorial team of experts has a unique opportunity to undertake the challenge of solving important scientific and health problems caused by vascular anomalies.


V.A. Cure project is the pioneer in education of researchers in rare diseases by using this highly integrative approach. V.A. Cure project aims to train young people to become creative and entrepreneurial researchers and the future leaders in the field of vascular biology.

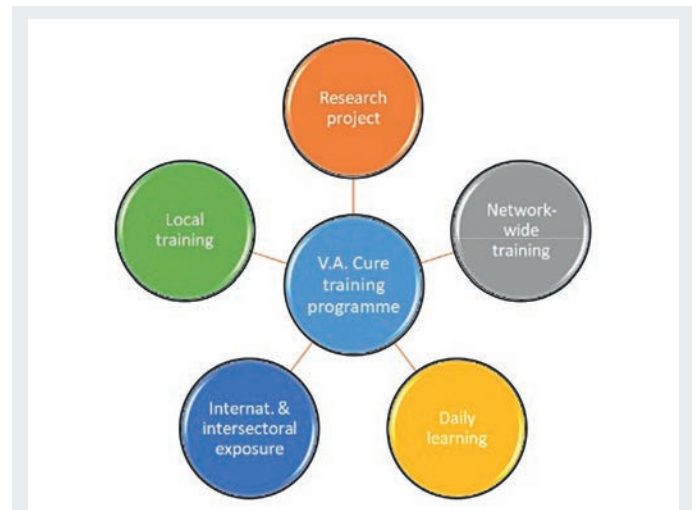

Figure 2: Structure of the training

Both graphics courtesy of: VACure Grant Agreement Number 814316 - H2020-MSCA-ITN-2018.

*** Editorial’s note:**
Content provided from: Project Consortium
Report prepared by: Project manager Mina Todorovic

 This project has received funding from the European Union’s Horizon 2020 research and innovation programme under the Marie Skłodowska-Curie grant agreement No 814316.

For more information visit our website:
www.vacure.eu
 If you are interested in what we do, you can follow us on Facebook page @VACure1
www.facebook.com/VACure1

If you are interested in what we do, you can follow us on Twitter @VACure1
www.twitter.com/vacure1
 LinkedIn page
www.linkedin.com/company/v-a-cure-project

Please scan ▼

V. A. Cure



Facebook



Please scan ▼

Twitter



Linkedin



Generated with www.qrcode-monkey.com

Generated with www.qrcode-monkey.com

Treatment of Vascular Anomalies at Multidisciplinary Centers*

Interview with Prof. Laurence Boon by Maria Barea (VASCAPA)

What are vascular anomalies and why are they complex?

Vascular anomalies are pathologies that affect the formation of the blood or lymphatic vessels. They are very complex due to their :

- Diversity: There are **more than 40 different types of them**; some affect the veins, others the arteries, or capillaries, or lymphatic vessels, some are combinations,... The majority of them are **rare diseases**: meaning that they affect less than 1 in 2000 people. Some are even ultrarare, affecting less than 1 in 50.000 people.
- Localisation: They can affect any body part where blood or lymphatic vessels go through. Hence, they can be present in the skin, mucous membranes, muscles or deep organs, such as lungs, spleen, liver or the brain. They **can be localized all over the body**.
- Evolution: their evolution and impact on the patient's quality of life can vary from one **patient to another and also throughout the patient's life**.

These complicated pathologies often require a complex, multidisciplinary and personalised management to guarantee right diagnosis and an optimal treatment for the patient.

How does a multidisciplinary center for vascular anomalies work?

In a multidisciplinary center, **all the doctors in the team are experts in their own field and also have knowledge in vascular anomalies. In addition, the multidisciplinary team gathers regularly to discuss medical cases** (diagnosis, management, treatments) as a group, in order to decide what is the best for each patient. In that way, each doctor knows what the others can bring and when, to secure an optimal medical care for the patient. It is very different than having the different specialties taking care of patients in their separate 'silos' in a hospital without such a coordination, disease specific knowledge and cross-field interaction.

The composition of the Centre for Vascular Malformations in Saint Luc University Hospital (Brussels, Belgium) is presented in figure 1 as an example. This reference center takes care of about 5,700 vascular anomaly consultations per year. In the weekly multidisciplinary meetings, the diagnostic and interventional radiologists, orthopedic surgeon, clinical geneticist, pathologist, dermatologist, plastic surgeon and the center's coordinator are present. The broader team is kept aware through internal communication and called in/ consulted when relevant, based on the patient's case.

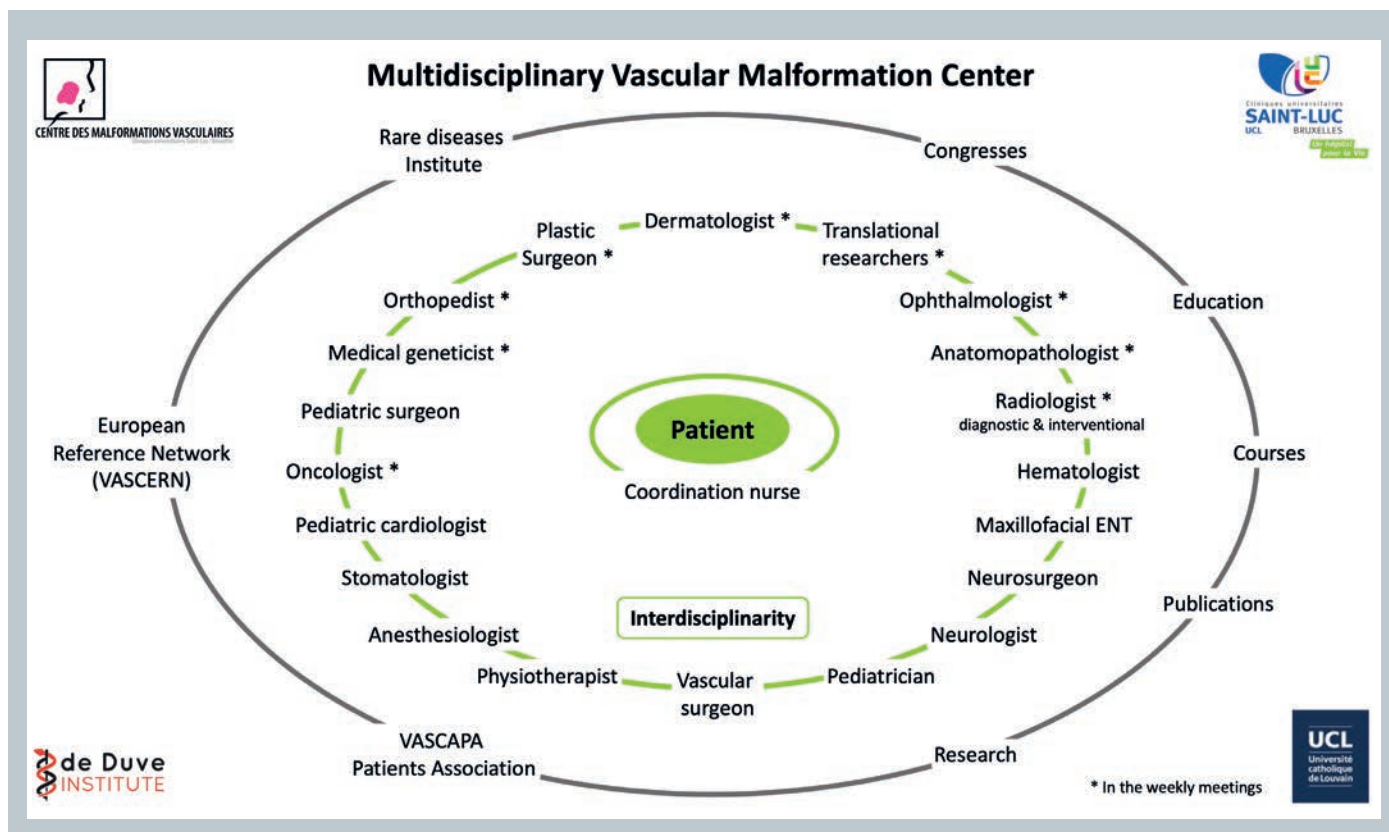


Photo: Prof. Laurence Boon

||| A multidisciplinary reference center aims to ensure for each patient and for each vascular anomaly, a precise diagnosis and the best possible treatment at the right time.

How are vascular anomalies diagnosis established?

It usually begins with a clinical examination performed by a specialist that will establish a clinical diagnosis (sometimes a preliminary one). When necessary, the team will perform complementary examinations to establish a definitive diagnosis. Some of the diagnostic techniques used for vascular anomalies include ultrasound, magnetic resonance imaging (MRI), catheter angiography, blood tests, biopsy and genetic testing. **A correct and precise diagnosis is the first key step for providing proper medical care**, because if the diagnosis is not correct, the treatment will not be correct. Hence it is a primary objective of a multidisciplinary center.

Why do vascular anomalies require care at multidisciplinary centers?

Vascular anomalies require multidisciplinary care because of their complexity (recall: diversity, localisation and evolution). For instance, a patient's disease may be a venous malformation, but given its location, it may have implications for many diverse organs and require follow ups from a wider range of specialists, going from a cardiologist to a neurologist passing by an ophthalmologist.

||| Once the diagnosis is established, the multidisciplinary team will be able to provide a holistic assessment and then a therapeutic decision for each patient after collegial discussion.

The individual treatment approach will be based on the characteristics, symptoms and location of the disease and the patient's life (age, quality of life,...). Whenever several treatment options are available, the team will decide the best type of treatment and the right order to have the best result for each patient. For example, the team could decide to treat differently two patients affected by the same disease (for example a venous malformation) due to their different age, different location of the malformation, different symptoms and evolution of the disease. Treatment options for the full spectrum of vascular anomalies go from conservative monitoring, custom compression garments, pulsed dye laser, pain-control medications, sclerotherapy, surgery, interventional radiology, drug therapy, and most often combinations of those. Frequently, a

repetition of one type of treatment or combination of them will be required. In many cases where a complete cure is not possible, good symptom control and quality of life will become the main goals of care.

||| It is important to remark that the evolution of certain malformations can be dramatically worsened if treatments are carried out by inexperienced physicians or if the initial diagnosis is wrong.


This is why it is important that a multidisciplinary reference team is involved in the diagnosis and treatment definition for a patient. Follow-ups can often be organised closer to patients' home, with limited follow-up visits at the multidisciplinary center.

How do multidisciplinary reference centers help improve care of vascular anomalies?

The improvements primarily come through four dimensions:

First, by concentrating the care of patients affected by rare diseases in medical reference centers the specialist doctors get to see the whole variability and facets in the presentation of the disease. This helps further increase their expertise towards diagnosis and disease evolution, which will then be applied on future patients' care. Similarly, the networking across expert centers is fundamental for improving care of ultrarare diseases.

Second, multidisciplinary reference centers will help patients avoid medical wandering, and all the bad consequences that often result from poor treatment or interventions made by non-specialist doctors, who meant to do well, but did not have the experience of an expert.



Third, reference centers help sharing expertise by participating on networks at national and European level. In the European Reference Network for Vascular Diseases (VASCERN), the VASCA-WG (Vascular Anomalies Working Group) aims to establish international guidelines (recommendations of good practices) for the care of vascular anomalies. Via the CPMS system they can offer expert consultations for challenging cases and the opportunity for doctors with no reference centers in their country to get advice on their patient's best care. Interaction between European and national networks allows a two-way flow of expertise.

Fourth, multidisciplinary reference centers can be involved in scientific research to identify possible causes of rare diseases through genetic research, in-vitro and in-vivo models. Close participation in scientific research has a two-fold benefit: it enables advancement on the fundamental understanding on these pathologies while strengthens the scientific knowledge of the multidisciplinary team. This in turns opens the possibility for clinical research on new medical treatments (>> see description of the discovery of Rapamycin treatment for venous malformations described in the article on page 40).

In addition, these centers also facilitate training of the future generation of experts (>> see also article V.A. Cure project on page 44) and raising general knowledge and awareness on these diseases. Important to add, the interaction with patient organisations: helping in their development and being supported by them for research.

Can I only be treated/ followed up at a multidisciplinary center?

Many patients will inevitable live far away from a multidisciplinary center. In general, patients can be followed up outside the center. The ideal approach is that the patient's diagnosis is done (or confirmed) at the expertise center, and then to come back for follow ups with a regularity that will depend on their condition. Additionally, whenever a special need appears or in case of clinical therapeutic trials.

For the rest of the time, the multidisciplinary reference center would have a network with other hospitals and doctors across the country so patients can be followed up closer to their home.

How can the European countries help to secure the functioning of multidisciplinary centers?

A reference center goes beyond giving the best possible diagnosis and care for patients. It will network with other centers to

improve care and treatment guidelines, participate in scientific and clinical research to improve therapeutic options, increase knowledge of these diseases among government and general public, training of future physicians, support patient associations, among many other actions. This type of centers are essential for the proper care and advancement on treatment of vascular anomalies (and in fact, also for all other rare diseases).



Prof. Laurence Boon

Photo: CUSL/ Hugues Depasse

For these centers to function properly, it is essential that they receive official recognition and adequate structural financial support. This recognition and support are also needed for the European Reference Networks (ERNs) and national expertise networks.

Expert diagnosis and proper treatment will not only increase patients' quality of life, but also decreases the number of unnecessary and costly exams.

*** Editorial's note:**
In this article we have used the Vascular Malformation Center of Saint Luc University Hospital (Brussels, Belgium) as an example of a multidisciplinary center. To note, this a reference center and not all centers are the same. The objective is not to establish the differences but to bring a good practical example. All the centers in VASCERN are multidisciplinary centers nominated by the health ministries of the respective countries to be able to be part of VASCERN. The list of these centers is available on page 74.

Prof. Laurence BOON
Coordinator of the Center for Vascular Malformations, Plastic Surgery Department, Cliniques Universitaires Saint-Luc, Brussels. Member of the Royal Academy of Medicine of Belgium.

▼ Please scan ▼

Generated with www.qrcode-monkey.com

TESTIMONIAL Being treated at a multidisciplinary center

Juan & Maria (VASCAPA)

What are the benefits of a multidisciplinary expert center for the patients? (perspective from a young patient's parents)

When our child was a baby, we noticed that sometimes half his face would turn very red. It is normal that people's face turn red when they are angry or make an effort, but not half of the face only. This was definitely a strange symptom that 5 different pediatricians categorised as perhaps being due to a mild hemangioma. With no clinical examination nor any tests, those different doctors told us not to worry, this was surely a non-issue. Fortunately, my husband researched via internet until he found a lead: a vascular anomaly could bring such symptoms. After bringing these findings up to our pediatrician and asking for a specialist in Belgium, our child was received at the Vascular Malformation Center (VMC) in Brussels, by Prof. Laurence Boon. Her diagnosis after clinical examination was soon confirmed with a doppler echography: he had an arteriovenous malformation (AVM).

That was 12 years ago.

During these 12 years he has been followed up at the VMC. As his AVM affects several body areas, he needs to be followed up by different specialists: ophthalmologist, stomatologist, and others. Finding the right specialist with knowledge on his condition has not been a challenge for us, as there was always a physician already part of the VMC's multidisciplinary team. At the hospital he has yearly checkups with the ophthalmologist, radiologist (for echo doppler and IRMs), stomatologist, neuro-pediatrician and plastic surgeon. We have also consulted with the ENT along the way and he has had some arteriographies to check the AVM's evolution. Throughout this time, he has undergone several treatments (such as embolisations) to manage the growth of his AVM, always at the VMC. These are procedures that are not easy, and with sometimes tough recovery. Fortunately, he has reacted well to these treatments and is now doing good, but we know we need to stay alert and continue regular follow ups.

For him, going to the hospital is not a big deal since he's grown used to it and all the medical staff of the VMC and Saint Luc's Hospital has

always been wonderful to him. Sometimes he needs to go more often but then months pass by when he doesn't go at all. He is now familiar with the medical team that looks after him; he trusts them, he sees them as caregivers that are doing the best possible interventions to improve his health.

For us parents, it reassures us that the expert team from the VMC is following him up.

We know the AVM is a complicated disease, and so far, on top of the regular follow up, whenever he required special medical attention the VMC doctors were there for him.

At some point the coordinator of the center put us in contact with VASCAPA, the Belgian patient association for people (and their relatives) affected by vascular anomalies. It has helped us a lot. To be able to talk with other parents that face similar challenges, to see children and adults with similar vascular anomalies that are overcoming the special challenges they face, others that are leading a good life despite their difficult health condition. It has complemented the holistic care he receives (in fact, that the whole family receives in a certain way).

For us, the VMC has become a precious place where the complexity of his disease is fully understood and managed. The doctor's work is fundamental for the quality of life of patients, and the clinical research they do give us hope that one day they will find a pharmacological treatment for AVMs.



Being able to talk to other parents has helped us a lot.

Future Options in the Treatment of Vascular Malformations

Dr. Friedrich Kapp, MD

The treatment of vascular malformations is based on weighing the discomfort caused by vascular anomalies, the benefit of treatment and the concomitant risks. In order to support patients suffering from vascular malformations, mainly surgery and interventional radiology procedures were available in the past. Some patients, however, cannot be treated with such therapies, e.g. due to an unfavourable localisation of the vascular anomaly. For these patients, alternative treatment options must be developed. Based on a better understanding of the genetic causes of vascular malformations, new medication therapies have emerged in the past few years. This pillar of therapy is becoming more and more important.

What characterizes vascular anomalies?

Generally, vascular anomalies are divided into vascular tumours and vascular malformations. The latter are defined regarding the diseased vessel section (>> fig 1). We distinguish between simple vascular malformations (capillary, lymphatic, venous, arteriovenous) and combined lesions (e.g. capillary-venous). Moreover, vascular malformations can appear in combination with other anomalies as a syndrome (e.g. Klippel-Trenaunay syndrome, CLOVES syndrome, Parkes-Weber syndrome).

Medical treatment of vascular malformations - State of the art -

The most frequent vascular anomaly is the infantile hemangioma, occurring in at least 4% of neonates. In almost all cases,

this phenomenon has a benign course and disappears on its own. A subset of hemangiomas show significant growth or is located in an unfavourable area and requires treatment. More than 10 years ago, physicians and medical scientists serendipitously found a significant reduction in infantile hemangiomas treated with the beta-blocker Propranolol. Following these observations, the efficacy of Propranolol was proven in an international study and market approval was obtained. Regarding complicated infantile hemangiomas, this medication has become the standard therapy for infantile hemangiomas. Unfortunately, it is the only drug approved in the field of vascular anomalies.

Of course, there are supporting medical therapies to relieve complaints, especially analgetics like Ibuprofen. Also, anti-coagulants (blood thinner) are additionally administered to dissolve painful blood clots occurring in venous malformations. Additionally, they can be used as a prophylaxis against a blood-clotting tendency. In this indication, we use heparins (e.g. Enoxaparin). In the past few years, oral medications have been developed as a substitute for heparin injections - the so-called direct oral anticoagulants (DOACs). Since especially in children, there is little expertise with these new drugs and their mode of action is not 100% identical to heparin, we still need to be cautious with this kind of treatment.

Further treatment options – insights from genetics

When discussing medical treatment of vascular malformations, Sirolimus needs to be considered as well. Within the past few years, this medication has become a very important treat-

TREATMENTS AND MEDICATION

Vascular Anomalies			
Vascular Tumors	Vascular Malformations		
Benign tumors	Simple	Combined	Combined + other anomalies
Locally aggressive and borderline tumors	Capillary (C) malf. Lymphatic (L) malf. Venous (V) malf. Arteriovenous (AV) malf.	e.g. Capillary-venous (CV) malf. Lymphatic-venous malf.	e.g. Klippel-Trenaunay syndrome CLOVES syndrome Parkes-Weber syndrome
Malignant tumors			

Figure 1

Photo: Dr. F. Kapp

ment option - especially in patients with lymphatic and venous vascular malformations not eligible for surgery or interventional radiology procedures. Now, why does Sirolimus have an effect on lymphatic and venous malformations, whereas it shows almost no effect on arteriovenous malformations? In order to understand this phenomenon, we need to have a look at the genetic causes of vascular anomalies. All cells are controlled by signals received that are transduced to the nucleus via signaling pathways and then trigger an organised cell behaviour such as cell division, growth

and the differentiation of cells and tissues. Vascular malformations are caused by various mutations that occur at the stage of vessel development leading to an excessive activation of certain signaling pathways and thus to an aberrant cellular behaviour, which may result in vascular malformations. These mutations mainly affect the so-called PIK3CA-AKT-mTOR and the RAS-MEK-ERK signaling pathways (>> figure 2). An excessive activation of the mTOR signaling pathway frequently leads to venous and lymphatic anomalies, whereas an excessive activation of the RAS signal pathway often results in arteriovenous malformations and certain complex lymphatic anomalies. These two signaling pathways are well-known in connection with diseases like breast cancer and malignant melanoma. However, it is important to emphasise that vascular malformations are not cancerous diseases and do not predispose to cancer, they only share the same changes in these signaling pathways. New therapeutic avenues may open up by using targeted drugs from cancer treatment (not chemotherapies!) in the field of vascular malformations.

Which targeted drugs can be considered?

• mTOR Inhibitors (Sirolimus and Everolimus)

Usually used as an immunosuppressant after organ transplant.

Especially Sirolimus is well-known in the field of vascular anomalies; it has already been successfully applied in many patients suffering from such diseases. Although complete recovery can usually not be obtained with this medication, it can stabilise the status, relieve complaints and reduce the size of the vascular malformation. In some cases, the therapy can be terminated after a certain period, however, part of the patients require long-term treatment. Due to inhibiting the excessive ac-

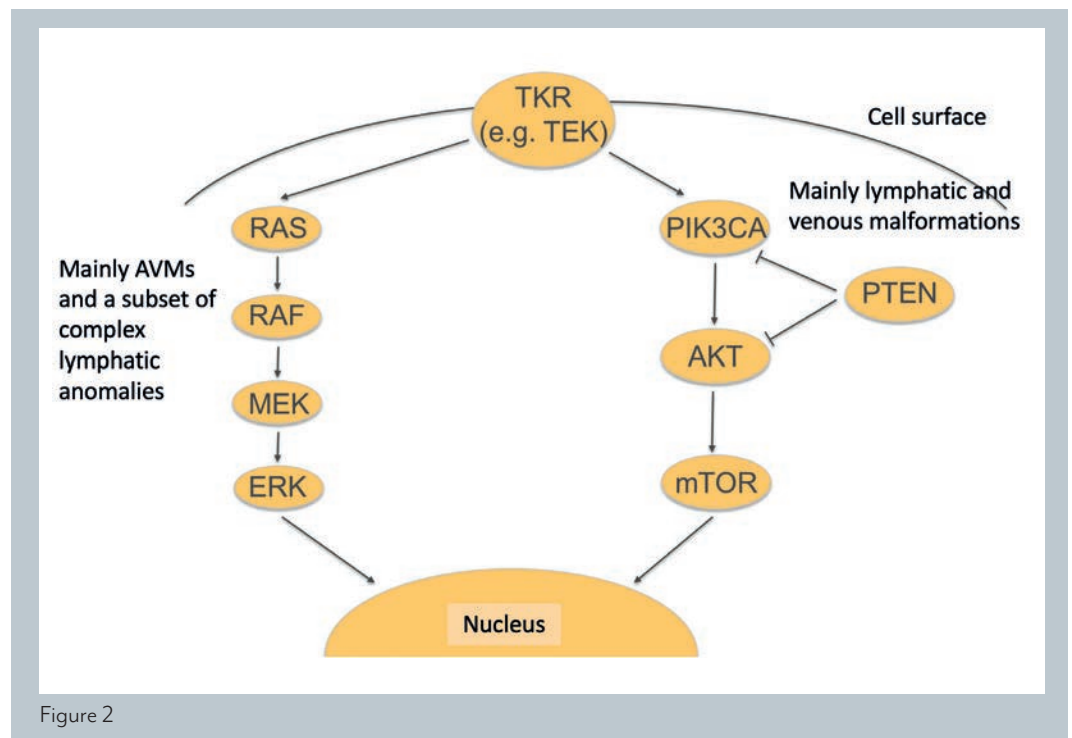


Photo: Dr. F. Kapp

tivation of the mTOR signaling pathway, Sirolimus mainly has a favourable effect on simple lymphatic malformations and on venous malformations. In arteriovenous malformations (with excessive activation of the RAS signaling pathway), however, it does not show an impact. Despite widespread use of Sirolimus in the treatment of vascular anomalies, the scarcity of controlled studies has prevented regulatory approval so far. However, one comprehensive study is currently being performed in Brussels, hopefully leading to an application for approval.

• AKT Inhibitors (Miransertib)

Developed for certain cancer diseases.

Miransertib inhibits the protein AKT1, whose hyperactivation causes the Proteus syndrome. A study on the efficacy in Proteus syndrome and in PIK3CA-related overgrowth spectrum (PROS) diseases is currently being conducted.

• PIK3CA Inhibitors (e.g. Alpelisib, Talselisib)

Developed for multiple types of cancers, approved for certain types of breast cancer.

PIK3CA inhibitors intervene directly at the cause of PROS diseases, the mutations in PIK3CA, by inhibiting the overactivated protein itself. A French study from 2018 showed good results in 19 patients with PROS disease. While the results were very encouraging, the data did not allow to gauge the therapeutic effect and safety of the treatment in larger patient cohorts with enough certainty. Since that time, this drug is administered in particular cases of serious illness, but there are patients that do not respond to this treatment. In order to better assess the efficacy of this therapy in the future, a well-designed study is required. Fortunately, the pharmaceutical company is already preparing an international trial expected to be launched in early 2021. The study will first recruit patients from

6 to 18 years of age as well as adults. Younger patients from 2 to 5 years are planned to be included at a later stage, as soon as results are available regarding the suitable dose and safety of the medication shown in the older age groups. Obtaining a better insight in the therapeutic effect of Alpelisib is as important as getting scientific data on the safety of the medication. A profound knowledge of both sides of the drug is essential for the next generation of patients as well. Even more so considering the fact that a similar study with Taselisib (also a PIK3CA inhibitor) in overgrowth diseases had to be discontinued due to safety concerns after unexpected serious adverse events occurred. Ultimately, a realistic assessment of efficacy and safety of Alpelisib and other medications require well-designed studies that may pave the way for market approval.

- **MEK Inhibitors (e.g. Trametinib)**

Approved for treatment of metastasized melanoma, among others.

Since Trametinib and other MEK inhibitors impede the RAS signaling pathway, they could perhaps be used in the treatment of arteriovenous malformations as well as in certain complex lymphatic anomalies. So far there are few experiences with MEK inhibitors for the treatment of vascular malformations, single cases of its use in Parkes-Weber syndrome and in complex lymphatic anomalies were reported at the international congress of the International Society for the Study of Vascular Anomalies (ISSVA) in 2020. In comparison with Sirolimus and Alpelisib, MEK inhibitors do not seem to be as well tolerated and side-effects are more frequent. Hence, further studies in this area are indispensable and urgently needed.

- **RAF Inhibitors (Dabrafenib, Vemurafenib)**

Approved for melanoma therapy.



Active member of the Federal Association of Congenital Vascular Malformations with the association's magazine and a patient for whom the information in it has been very helpful in her disease progression.

Photo: K. Sachse

So far, there is hardly any knowledge on the use of these inhibitors in vascular malformations. If a causative BRAF mutation is identified and other therapeutic options are not available, the use of a BRAF inhibitor might be considered as a targeted treatment. However, efficacy and safety is not known at the moment and adverse events also seem to be common, as in MEK inhibitors.

- **Thalidomid**

Approved for the treatment of lymphoma.

Thalidomide does not act directly on the signaling pathways mentioned above, but the exact mode of action is not completely known so far. In the field of vascular anomalies, some centers use this drug in bleeding arteriovenous malformations in case no other therapeutic options are available. However, the number of treated patients is still low and further studies are needed to further evaluate the use of thalidomide.

Open questions and outlook

There are still many open questions like the following ones:

- What is the best time to initiate an experimental drug therapy in the treatment course?
- Does treatment require a genetic analysis with confirmation of the causative mutation?
- How long may/should/must such an experimental therapy be applied?
- Are targeted therapies superior to conventional ones and how to find the most suitable therapy?

In order to address these questions and benefit from drug development in other medical areas, especially from oncology, well-designed multicenter studies in the field of vascular malformations need to be conducted. In these studies, new experimental therapies are investigated and patients and their course of disease are closely monitored to ensure that future patient generations benefit from these experiences. With these studies new drugs might then obtain market approval. For new medical treatments, it is a long way to achieve this goal, but it is well worth the effort!

Despite all these developments of therapeutic options, the decision for suitable treatments should always be made by an interdisciplinary team together with the patient in order to achieve the highest possible level of care for the patients.

Dr. Friedrich Kapp, MD
 Division of Pediatric Hematology and Oncology
 Department of Pediatrics and Adolescent Medicine
 Medical Center - University of Freiburg (Germany)

TESTIMONIAL Sirolimus treatment since birth

Shanti (VASCAPA)

Nora was born with a big lymphatic malformation in her neck. It extended from her right jaw, through her shoulder into her chest. Her breathing and swallowing seemed to be ok during pregnancy, so we took a leap of faith! At birth, she did not need intubation, but her blood saturation was low, so she was kept in neonatology for a few days.

The malformation, containing both micro- and macrocystic components, was big at birth. And to prevent its growth, Nora started Sirolimus at 7 days old. We gave it to her with a syringe, at the back of her cheek, and we would rinse with water or milk afterwards. We started to do this because in the beginning we did not rinse and she got a big painful blister in her mouth. She never protested on the flavour, maybe because she got used to it so early.

Sometimes I found it a hassle to take the cooled Sirolimus with us (she had to get it 3 times per day). On a trip the hotel fridge was sometimes very inaccessible, the syringe would leak when not put away correctly,.. But overall it went fine. We protected her as good as we could against becoming sick. Almost nobody was allowed to touch her, we would disinfect our hands every time before we would touch her,.. Only with her one year older sister we were not so strict, as we really wanted them to bond.

At ten months she started to go to daycare. But we had to keep her home often due to infections (bacterial). So we started a

low daily dose of antibiotics and she was less often and less severely ill.

We did not experience any negative side effects from the use of Sirolimus and we assume it did have a positive effect (hard to tell as there is no comparison possible to not using it). She did need a lot of blood analysis to determine the right dose (because at that age they grow/gain weight so rapidly), which was especially a nightmare as she had almost invisible veins.

Her malformation grew and shrank, it was very unstable.

At the age of 1 year and 5 months, she got surgery, which went very well. A big part of the malformation, the accessible part, was resected. After this, she got all the infections possible (flu, stomach flu,...) by coincidence.

And when she had a fever, she was not allowed to take Sirolimus, so we stopped and we weren't able to restart for over a month.

And that went fine. So fine, we were told it was ok to not start again and see what happened.

And so far, apart from once a bad infection in the remaining part of her malformation that went just fine, she is doing great!

TESTIMONIAL IMPLEMENTATION OF SIROLIMUS in the context of the VASE study

Tamara & Franck (VASCAPA)

Our son Raphaël suffers from an orphan disease: Generalized Lymphatic Anomaly. At present there is no treatment to cure it. It is a vascular malformation that reveals in the form of lesions throughout his body (viscera and bones). The treatment of this pathology is surgical, but has its limits. After several years of facing the harsh reality of this disease, we finally found a treatment that could slow down the progression of his malformations: SIROLIMUS through the VASE study (VASE = Vascular Anomalies Sirolimus-Europe). We know it is not a cure, but it represents a treatment and an improvement option today.

This is the story of our journey for setting up the Sirolimus treatment as part of the VASE study. We hope it can help or guide others on theirs.

First contact with the doctors and implementation of the treatment:

Our advice: think of establishing in advance, a list of your questions to ask the doctors; about the treatment, side effects, follow-up, etc.. Because during the appointment, people can lose track with all the information given (which is quite normal) and forget questions that will remain unanswered. Do not be afraid to take out your sheet of paper, and combine the new information you just received with your questions. You will be happy to be able to read all again once the appointment is over.


During our first appointment, Raphaël had molluscums (small benign skin warts of viral and contagious origin, which are common in many children). As Sirolimus treatment is an

immunosuppressant (i.e. it slightly lowers immunity), there was a risk that they would further spread. So we had to have all of his molluscums removed, before starting his treatment. We were also asked to take a blood test to analyse whether Raphaël was immune to chickenpox before starting the protocol. Once his molluscums problem had been resolved, we were able to begin his treatment during a second appointment. Raphaël has a weakened and somewhat reduced respiratory system. It was therefore agreed with the doctors to add an antibiotic therapy 3 days a week for the duration of Sirolimus. The purpose of this antibiotic is to protect our son's lungs from any side effects of the treatment.

We started his medication on March 13, 2020 and thus entered into the protocol of the VASE Study. Unfortunately, the health context with COVID has complicated things. Indeed, vigilance with regard to this crisis and Raphaël's (respiratory) pathology has been reinforced. The context for this long-awaited treatment was quite anxious. Nevertheless, the medical team was able to reassure us about the situation and we are happy that we have maintained the protocol.

First contact with the doctors and implementation of the treatment

It is important to know that the medication is available as an oral solution for children (2 doses per day at a fixed time for Raphaël), and has to be kept refrigerated. So remember to take a cooler to transport the bottles during your appointments or any other travel. Sirolimus has no real taste and is therefore easy to administer to children. Adherence to treatment is a challenge in the family planning but not impossible at all. In fact, it is necessary to pay attention not to forget to take the medication!



Drawing by Raphaël at the start of treatment

The treatment was implemented gradually. For the first 3 months, it was necessary to return to the clinic every month to make a blood test, to define whether or not the dosage needed to be adjusted. Then at the end of the 3 months the consultations were spaced out and the appointments were only made every 3 months. The study is based on 2 years, but it is important to know that treatment can be stopped at any time. It is obvious that the risk-benefit balance is applicable in this protocol. We were asked to perform an MRI before starting the treatment, to have a reference point. Then a second MRI after 1 year to observe the effects of the treatment on the evolution of the pathology. In the case of our son, it will be established a little earlier because his lesions are internal, so they are not visible from the outside.

Side effects and patient's follow-up

For our son, the side effects were less severe than we expected. Nevertheless they are present. At first there were mouth ulcers; thought they were quite large, they were not very disabling as they were quickly relieved with the help of an anesthetic product. There was some abdominal pain in the evenings, joint pain the first month, headaches and a few days of severe fatigue. But to be clear these disorders did not appear all at the same time, but it was only a few times a month. We noticed that these side effects increased with each readjustment of the treatment, and that they diminished with each passing week once the new dosage was assimilated by his body.

The patient's follow-up is done via the appointments, and also through an email and phone number that were communicated to us. So we can contact a doctor from the study in case of any questions or problems. And this was a good way to reassure us! Additionally, the treatment might need to be interrupted if the child is ill. So the contact information might become necessary for the child's treating physician or pediatrician to know the protocol to be followed.

To sum up, there is nothing insurmountable!

We are rather satisfied by the ease of the implementation of the treatment, which offers a certain flexibility. The treatment did not impact the quality of life of our son Raphaël and we have noticed some external signs that seem promising and encouraging regarding the effectiveness of Sirolimus. This is the beginning of our experience with this treatment. Please do not forget that this is our personal experience, and that yours may be different. We hope that this testimonial can help and reassure other families.

Intranodal Lymphatic Imaging and Treatment

Imaging and Treatment of Lymphatic flow abnormalities

Willemijn M. Klein, MD, PhD

Introduction to lymph

All people are familiar with blood that circulates in the body driven by the heart. There is another circulated fluid in the body that is less known but just as important: lymph.

Lymph is the fluid that is in the interstitium (between the cells) of the body. It circulates through lymphatic vessels and lymph nodes in the whole body.


Lymph flows into the blood circulation, in particular the main lymphatic vessel that is called the thoracic duct, that drains into the left subclavian vein. Lymph contains white blood cells and has a role in the immune system, as you may notice as colourless fluid in a wound. Lymph from the liver is rich in proteins. Lymph from the bowels is a milky white fluid that contains a large amount of fat; this is called chyle. Lymph and chyle have an important function in providing the body with energy and building materials.

Despite its importance, lymph seems to be a much forgotten or neglected body fluid in medical science and imaging. Although lymph has been described since the old Greek, first by Hippocrates even 5 centuries before Christ, knowledge of the embryology and anatomy as well as knowledge of lymph function and of lymphatic disorders is largely unknown and much is to be discovered yet. This goes especially for the normal and abnormal flow and leakage of lymph and chyle. The invention of the intranodal dynamic MRI lymphangiography (DMRL), performed with contrast injection into a lymph node, gives a great amount of information on lymph flow diseases and creates a renewed interest in lymph.

Imaging lymph

The imaging of lymph and lymph flow is very challenging, since lymph vessels are very small and lymph flows very slow. To visualise the flow in the central lymph vessels a contrast material that stays within the lymph vessels is needed (which is dependent on the type and size of the molecule) and a scanning modality with a high resolution. This is achieved with intranodal dynamic MR lymphangiography. The contrast is injected in a lymph node below the groin and then flows straight to the central lymph vessels in the back of the abdomen (retroperitoneum) and chest (thoracic duct). Any obstructions or leakages in this part can be visualised. A caveat is that the important side branches in the liver and mesentery (bowels) are not upstream and will only be visible in case of backflow. The same goes for backflow in legs and lungs. Therefore it may be helpful to make some images after walking and jumping!

Lymph edema of an extremity (after oncology treatment, trauma or without any obvious cause) can be imaged with other techniques. It may be an indication for *lymphoscintigraphy*, consisting of a nuclear tracer injected subcutaneously between the toes or fingers and traced with a gamma camera. Lymphography can also be performed with *indocyanine green* injected subcutaneously and a near infrared camera system to visualise the superficial lymph vessels. Both methods are not suited for the central lymph vessels in the thorax and abdomen but have a role in diagnosing lymph flow in the arms and legs.



Willemijn M. Klein, MD, PhD

Photo: Willemijn Klein

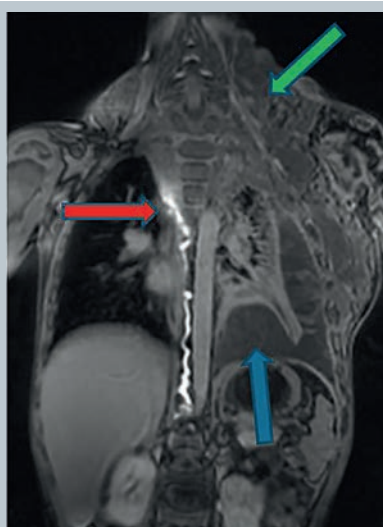


Figure 1: Intranodal MR lymphangiography.

Young boy suffering from a venous malformation (green arrow) and chylothorax (blue arrow). Contrast is leaking out of the thoracic duct (red arrow) into the pleural space.

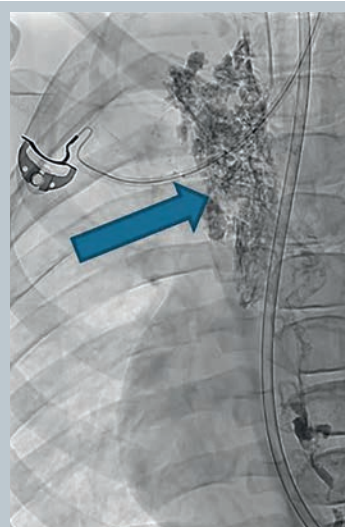


Figure 2: Radiography of the thorax after

Learning DMRL

In regular CT and MRI scans, contrast material is injected into a vein, which flows into the blood circulation and en-

hances the organs. However, the contrast does not flow back into the lymph vessels and therefore no information is obtained about lymph flow. Radiologists Itkin and Dori in Philadelphia, as well as radiologists in Boston, have pioneered the intranodal contrast injection to get information of the lymph flow. By placing a needle in a lymph node in the groin, the injected contrast material flows into the lymph vessels. When scanning many times, the flow of the contrast in the lymph vessels and thoracic duct can be visualized dynamically.

||| This invention seems a turning point in the acquiring of knowledge of lymph flow.

Although the scanning protocol with the intranodal contrast injection may sound rather logical and easy to do, it has been quite difficult for me and my co-workers to get it properly done. We have been very happy and lucky to be welcomed by Max Itkin in Philadelphia, to learn the intranodal technique. In the Hospital of the University of Pennsylvania my colleague Professor Leo Schultze Kool and I learnt how exactly to place the intranodal needle, how to place the patient in the scanner and even how to perform intranodal embolisation of leaking lymph vessels. With this experience we were able to properly implement the DMRL into our own practice in the Radboudumc, Nijmegen, the Netherlands.

||||| Today, over 70 patients suffering from chylothorax, scrotal chyle leakage, plastic bronchitis, central lymph edema and systemic lymph flow diseases have found us for the diagnostic intranodal MRI scan and therapeutic interventional radiology.

We want to help other radiologists from other vascular malformation teams to implement the DMRL technique. Therefore we organise online sessions to discuss difficulties with the scanning technique via Vascern Webex meetings. In 2021 we will present a face to face workshop with lymph specialists, which is sponsored by the European Joint Programme on Rare Diseases (EJP-RD).

Indications for imaging

A DMRL is indicated in case of suspicion of abnormalities in the central lymph flow in thorax and abdomen. A chylothorax is a leaking of chyle into the pleural space (around the lungs), which can be caused by a leak in the thoracic duct or an abnormal routing of chyle from the bowel (mesenteric) lymph vessels. In case of a chylopericardium the leaking is in the pericardium; in case of chyloascites the leaking is into the abdominal space. A patient suffering from leakage of chyle or lymph through the scrotum or vagina probably has abnormal lymph vessels in the pelvis or retroperitoneum. Plastic bronchi-

tis is the leaking of chyle into the airways, which can be originating from the thoracic duct. Protein losing enteropathy is likely caused by retrograde flow in the mesenteric (bowel) lymph vessels. All of the above mentioned lymph flow abnormalities may be a single symptom in a patient. However, a patient may also have several symptoms, especially in syndromic cases such as Noonan syndrome and General Lymphatic Anomaly (GLA) patients. The intranodal DMRL is not indicated for peripheral lymph edema, which are the cases suspected of a lymph flow problem in the arms and legs and not in the central lymph vessels. This may be either primary lymph edema or secondary to, for instance, peripheral lymph node dissection for oncology or a trauma. In those cases other types of lymphangiography can be made after contrast injection subcutaneously between the fingers or toes.

Therapeutic options

If the DMRL demonstrates a leakage of lymph or chyle, embolisation can be performed by a specialised interventional radiologist. Via the intranodal technique the lymph vessels can be visualised with contrast material such as the fatty Lipiodol. A very thin catheter can be placed through the abdominal wall into the thoracic duct to embolise the leaking spot using glue or a coil. In some cases with leaking of chyle, it may be a better option to prescribe a diet with only medium chain triglycerides (MCT, a type of fat), that diminishes the chyle flow from the bowels. The lowering of the chyle flow may be helpful for the leaking to stop. In case of obstructed lymph vessels it may be an option to make a venolymphatic anastomosis. This is a microscopic operation performed by a specialised plastic surgeon.

Prospects for patients

||||| The DMRL is a new diagnostic manner to find the location and the cause of central lymphatic flow disorders.

Patients now can have a proper diagnosis which is great step forward. Because with this very precise diagnosis, a treatment comes within sight. Many patients have been treated so far and many showed great improvement. However, one needs to realise that the imaging may also give insight into abnormalities that cannot be treated (yet). Further scientific studies are needed, especially to improve the indications for diagnostic and therapeutic intranodal imaging and to know the long term effects of treatment, including the quality of life and cost effectiveness.



Willemijn M. Klein, MD and PhD

Amalia Children's Hospital, Pediatric radiologist
Radboud University Medical Center

○ Willemijn.klein@radboudumc.nl

Transversal Working Group on 'Pregnancy and Family Planning'

Petra Borgards (Member of the board of the Federal Association of Congenital Vascular Malformations)

Pregnancy and family planning are important issues for everyone. For people with rare diseases, who already face great challenges in terms of diagnosis, treatment and social aspects of their disease, anything to do with pregnancy and family planning is often an anxiety-provoking topic. Why? There is too little secured knowledge about the particular risks and difficulties that can arise prior to, during pregnancy, childbirth and afterwards for women affected by rare diseases, apart from passing on the disease to future or already conceived children (heritability).

For these reasons, a transversal working group with representatives from all ERNs was built up and began its joint work in 2020, developing over the year into an active working community. It is chaired by the ERN ReConnet coordinator Marta Mosca, associate Professor of Rheumatology at the University of Pisa, and has the following structure: 3 representatives from each ERN: one health care provider representative, one patient representative, the coordinator (optional); suggested ERN-internal sub-groups.

VASCERN nominated the following members for the group :

- **Prof. Guillaume Jondeau**, Cardiologist, Paris (Coordinator of VASCERN)
- **Prof. Julie De Backer**, Cardiologist and clinical geneticist, Gent (HCP representative)
- **Petra Borgards**, Federal Association of Congenital Vascular Malformations, Germany (patient representative)

and has founded an internal pregnancy Task Force during the VASCERN online meeting in October 2020.

Aims of the ERN transversal group

- Stimulate research in this field.
- Deliver specific Clinical Practice Guidelines for pregnancy planning and management.
- Develop patients and healthcare professionals education and information.
- Collect European wide evidence on the management of this specific condition.

Topics and Priorities related to Pregnancy and Family Planning

1. Monitoring of pregnancies, delivery and outcomes.
2. Medicines during pregnancy and lactation.
3. Family planning and counselling.
4. CPGs & Clinical Decision Making Tools: state of the art and unmet needs.
5. Fertility preservation and assisted reproduction.



On the recently launched web page of the working group, the names of the members have been published and content related to the diseases covered by VASCERN. The page is constantly being updated with existing or new material and content.

vascern.eu/new-vascern-pregnancy-and-family-planning-wg-page/

Generated with www.qrcode-monkey.com

Photo: vascern.eu/new-vascern-pregnancy-and-family-planning-wg-page/

6. Contraception.
7. Post pregnancy, management of the new-born.
8. Parenthood and rare and complex diseases.

The results of the prioritisation of the topics were discussed among the whole group and were prioritised differently by the ERNs. The role of the ERN wide working group is now to find and work on issues that apply generally to all rare diseases. These basic topics are then to be supplemented and worked on in the internal working groups with the disease-specific problems and topics.

Surveys

In order to obtain a factual basis for working on the various topics and achieving our goals, two surveys will be conducted in the first half of 2021:

- one on medical issues by the health care providers in the pregnancy group,
- the second by the patient representatives.

The surveys will be conducted anonymously without collecting personal data on a secure EU server and are intended to reach the highest possible number of women with rare diseases through wide publication beyond the ERN. The survey results will feed into a planned multi-day workshop of the whole group in mid-2021 which should lead us to further action.

Contact:
 We would be happy to receive feedback and support.
 Prof. Julie De Backer
 (The chair of the VASCERN internal group: HCP)
 ● Julie.DeBacker@uzgent.be or
 Petra Borgards (The patient representative)
 ● borgards@angiodyplisie.de

Treatment of vascular anomalies with Surgery, Embolisations, Sclerotherapy and Laser

Nader Ghaffarpour, MD, PhD and Caroline T. van den Bosch MSc

Laser therapy

This therapy can be used for:

- Capillary malformations
- Hemangiomas (to treat residual tissue)

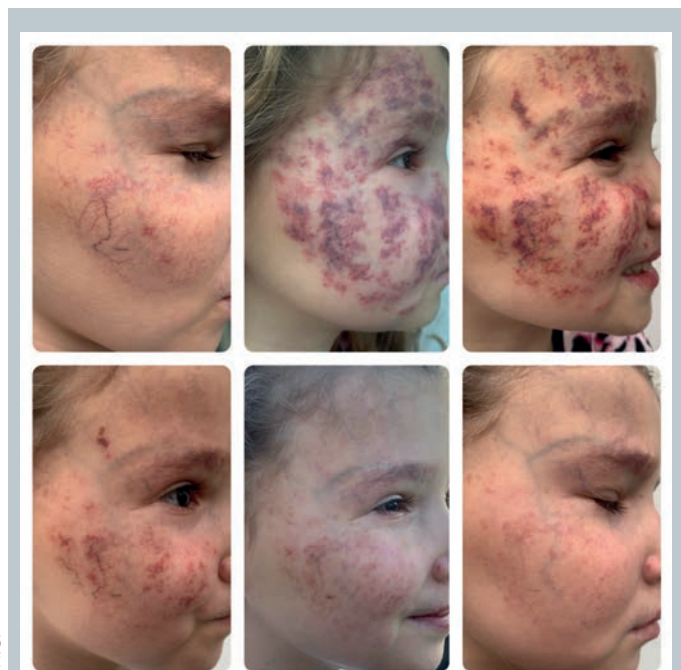The size and location of the vascular malformation determine whether laser therapy may be successful. Unfortunately, some skin disorders do not respond to laser treatment. It is impossible to predict in whom the treatment will be successful.

Procedure

Short pulses of laser light are shone onto the vascular abnormality using a laser lamp. The red blood cells absorb the laser light. This causes the abnormal blood vessels to break down and shrivel up. The surrounding skin remains healthy. During the treatment you/your child will wear glasses to protect the eyes from the laser rays. A laser treatment can feel as if it stings or as if a lot of rubber bands are being shot against the skin.

Anesthetic

For adults and older children an anesthetic ointment (EMLA cream) may be sufficient. Sometimes the doctor can numb part of the face with an injection. Small children are often put under anesthesia.



Patient treated with laser therapy

Photos: N.G.

After the operation

The treated area will look purple to black immediately after the procedure and will remain so for approximately 10 days. You can apply anaesthetic ointment to ease the pain. Sometimes a scab will develop after the treatment, which will disappear after a few weeks.

Results of the treatment

Every person and every vascular malformation react differently to laser therapy. One treatment is almost never enough. The vascular malformation must be treated several times at intervals of 6-8 weeks. The aim is to reduce the colour. This makes the anomaly less noticeable and makes it easier to camouflage with make-up. It is seldom possible for the vascular malformation to disappear completely.

Because the underlying (genetic) cause is not removed by the laser treatment, the result is often not permanent. After 5-10 years the colour can return because the vessels expand again. It does not matter whether the laser treatment is done at a young or older age. The result is the same.

Surgery

Surgery to remove or reduce a vascular malformation is used for:

- Venous malformations
- Arteriovenous malformations*
- Lymphatic malformations
- Capillary malformations
- Infantile hemangiomas

*Before surgical removal of an arteriovenous malformation, embolisation is often performed. This reduces the risk of bleeding during the operation.

Surgery is a perfect solution for smaller, superficial and well-defined vascular malformations when possible to excise in total. Often however the malformation cannot be completely removed. Surgery is then used as a compliment to other treatment modalities. Surgery is used for example to debulk big tissue malformations on patients with i.e., Klippel-Trenaunay Syndrome as part of a multidisciplinary approach combined with both sclerotherapy, laser and medications both Sirolimus and anti-coagulation treatment.

However, surgery has limitations and potential complications must always be taken into consideration. Complications may be postoperative wound healing difficulties, pain, infection or nerve injuries as well as accidental surgical hazardous event to adjacent vital structures. Hence, larger surgical procedures

must always be done by experienced surgeons within multi-disciplinary teams dedicated for vascular anomalies.

Surgery is considered when:

- The malformation causes many complaints (e.g., bleeding, severe pain or recurring infections).
- Part of the malformation remains after another treatment and previous treatments have not helped sufficiently.
- Repeated sclerotherapy sessions (>4 times) have been insufficient.
- Sclerotherapy is considered hazardous due to the risk of compromise to adjacent vital structures such as the air ways in case of post-sclerotherapy swelling.

Procedure

The surgeon cuts away the entire vascular malformation or reduces part of the malformation and then closes the skin. After the operation the surgeon may need to remove tissue fluid from the wound with ultrasound guided needle puncture for several weeks to facilitate the healing process. When removing large vascular malformations, a skin graft or muscle flap may be necessary to replace the tissue that has been cut away. However, this happens only very rarely.

Anesthetic

The operation is performed under general anesthesia. After the operation, the area is painful. The patient will receive pain-killers for this.

Results

There has been little scientific research into surgery for vascular malformations. Therefore, there is not enough good information about the results and complications. Sometimes years after the surgery symptoms from the remains of the malformation may recur. In such cases further surgery or other complementary treatments such as sclerotherapy or medical treatment may be mandated.

Sclerotherapy and embolisation

These treatments can be used for

- **Arteriovenous malformations**
- **Venous malformations**
- **Lymphatic malformations**

Injection treatments: sclerotherapy & embolization:

Sclerotherapy and embolisation are terms that are often used interchangeably. By both, it is meant that the deviant vessels of the vascular malformation are closed off. There are two ways of doing this:

1. by inserting something that blocks the blood vessel (embolisation) - **or** -
2. by damaging the wall of the blood vessel in such a way that the blood vessel becomes blocked (sclerosing).

Treatment of venous or lymphatic malformations (sclerotherapy)

In the abnormally shaped veins or lymphatic vessels, the blood or lymph fluid flows very slowly or stops. Expansion of the malformed blood vessels due to, for example, clotting of the blood or reaction to infection can cause pain and congestion. The treatment consists of injecting a liquid through thin needles that are inserted through the skin. This damages the wall of the veins/lymph vessels, causing an inflammation reaction. The treatment eventually causes the vessels to shrivel up and the defect to become smaller. The term sclerotherapy is used for these treatments. There are various agents available to carry out these treatments, including alcohol, Aethoxysclerol, Aethoxysclerol-foam, bleomycin, OK432, STS.

The choice of the agent to be injected will depend on the location of the abnormality, its extent and the complaints. The risk of complications must also be assessed. If, for example, the deviation is very superficial (in the skin) or if the deviation runs along a large nerve, an assessment will have to be made of which fluid can best be applied with the least risk of complications. The choice of the type of fluid is also determined by the practitioner's experience with the fluid in question, which may lead to different considerations per center.

Especially with extensive venous or lymphatic malformations, one treatment session will not suffice. Often several treatments are necessary to achieve sufficient reduction of complaints such as pain. Sometimes the pain reduction is insufficient, and it is necessary to switch to one of the other treatment options. This decision will always be made within multidisciplinary teams and together with the patient.

The treatment of arterio-venous malformations (AVM) (embolisation)

AVMs constitute of abnormal connections between the arteries and the veins. Capillaries are the connection between the artery and the vein. In an AVM, the diameters of the deviating capillaries are larger than the diameters of normal capillaries, causing the arterial blood to be discharged into the veins more quickly. The cluster of deviating capillaries forms the core of the AVM and is also called the AVM's nidus. The composition of the nidus depends on the number of deviating capillaries and the way they are connected to the veins. The treatment of an AVM consists of closing off these abnormal capillaries. This type of treatment is called embolisation. How the embolisation is carried out will depend very much on the composition of the nidus. Before a treatment plan can be made, the nidus will first

be assessed by means of an angiography. The treatment of an AVM requires a high degree of expertise. If the abnormal capillaries are not closed, there will be a high risk of recurrence, as the cause, the abnormal capillaries, will not have been removed. Many agents (alcohol, onyx, coils), either alone or in combination, are used to close off the capillaries. The agents can be introduced via a catheter into the blood vessel or via needles inserted directly into the nidus through the skin. Very often, several procedures at intervals of several months are necessary to finally achieve complete closure of the nidus. If this is successful (in 60-70% of cases), the AVM is completely eliminated and will not recur. If this is not completely successful and the nidus can only be reduced in size, the symptoms will have diminished, but there is a risk of a recurrence in the future.

Anaesthesia

All AVM treatments, as well as most venous and lymphatic malformations, are performed under general anaesthesia or deep sedation. Only if the venous or lymphatic malformation is located very superficially in the skin, local anaesthesia (or no anaesthesia) may sometimes suffice.

Day treatment

Most vascular malformation treatments are performed in day surgery. Only in case of special circumstances, admission for a number of days is necessary. This will be discussed with the attending physician and the patient.

Postoperative/recovery phase at home

The recovery phase and the expected symptoms at home will strongly depend on the type of vascular malformation and the extent of the defect. The swelling of the treated area can last up to 6 weeks and can sometimes cause pain. In most patients, the swelling subsides considerably after 1-2 weeks. This too will be discussed in detail during the treatment plan.

Who does this kind of treatment?

The treatments are performed by one of the team members. Depending on the complexity and the equipment needed, this may be the dermatologist, surgeon or interventional radiologist.

Combined interventions

Sometimes embolisation or sclerotherapy is performed together with surgery, or after a series of embolisation or sclerotherapy treatments, the residual defect is removed by surgery. Such a treatment plan will be discussed with the patient in detail.

General: Preparation for treatment

In preparation for the treatment, you will be asked a number of questions regarding medication and allergies. If you are taking

blood thinners, the doctor will advise you whether or not you should stop taking these medicines. If you are hypersensitive to contrast medium, please inform your doctor and the radiologist. Precautions can then be taken to reduce the risk of an allergic reaction. When contrast medium is used, there is a risk of worsening renal function in people with renal dysfunction or diabetes. Precautions can be taken to reduce this risk.

Support stockings

Possible treatment for

- Venous malformations
- Lymphatic malformations


Support stockings (therapeutic elastic stockings) are often used in case of vascular malformations of the arms or legs. The pressure of the stocking improves the drainage of blood and lymph fluid, thereby reducing swelling. The purpose of a compression stocking is to alleviate the symptoms, not to cure the malformation or to prevent problems such as an open leg. In addition, compression stockings can reduce the risk of arthritis, thrombosis and pulmonary embolism.

Procedure

The stocking will be worn during the day. The support stockings are meant to be worn every day for a longer period of time in order to maximise the effect of the treatment. Personalised compression stockings are recommended. This should be discussed with your doctor.

Results

Doctors' and patients' experience show that compression stockings fitted by an experienced bandage maker can reduce the symptoms of vascular malformations.



Dr. Nader Ghaffarpour, MD, PhD

Photo: VASCERN

Adapted with permission from Dutch network of centres of expertise for vascular anomalies
www.aangeborenvaatafwijkingen-expertise.net/het-expertisenetwerk

Nader Ghaffarpour, MD, PhD
 Department of Reconstructive Plastic- and Craniofacial Surgery, Vascular Anomaly Center
 Karolinska University Hospital Stockholm (Sweden)
nader.ghaffarpour@sll.se

Experiences of patients and relatives in diagnosis, treatment and living with vascular malformations

Maria Bäumer (Member of the board of the Federal Association of Congenital Vascular Malformation)

What does it mean to live with a congenital vascular malformation?

Answers from patients of the 'Bundesverband Angeborene Gefäßfehlbildung e.V.' (Federal Association of Congenital Vascular Malformation, Germany)

‘With everything that makes me, I can't think of myself differently and my leg and the history associated with it are part of it. I try to adapt my lifestyle to my possibilities. This often means retreat. If I am doing well, I throw myself back into life completely.’ (D.G.)

It does not exist: THE one life plan with a congenital vascular malformation. Actually, there never is THE one perfect life plan - neither for chronically ill nor for healthy people. But for people with a chronic disease, in addition to life's 'normal' hurdles and blows of fate, which often call for massive flexibility and adaptation, there are also the hurdles caused by the disease itself. They constantly put additional stumbling blocks in one's way, costing lots more effort a fact which is not often recognised. This impinges on the psyche and the social environment of those affected. People deal with it in very different ways, so that there is a whole range of aspects that need to be considered, or as to where in fact professional help and simply understanding are required.

In this section, we focus specifically on the psychosocial effects and in the following editions, we will try to deepen today's overview of the many different aspects. The course and development of a disease are just as individual as the experience of the disease and its consequences. Congenital vascular malformations always affect the whole person. Physical, psychological and social well-being are also influenced by social factors. Nowadays a person's appearance and their achievements play a major role in the way he or she is perceived – regardless of one's own attitude towards it. It is already at school that the process of comparison-making leading potentially to marginalisation begins.

‘Some people stare. Others look away. That has accompanied me all my life.’ (W.H.)

Having a different appearance due to a naevus or hypertrophy, being limited and vulnerable suffering from spontaneous bleeding and pain, displaying an unusual gait pattern or being

less capable; many patients experience the feeling of being 'different, of not conforming to the "norm"'. Often this feeling of 'otherness' is generated or exaggerated by someone else, either unconsciously or consciously, even if the motives of the person delivering the message often lie in a wish to aid and support. Breaking (or at least attempting to break) this self-affirming cycle between one's self-perception and that of others and establishing a self-acceptable quality of life, concurring with the norms of social cooperation, succeeds for some apparently effortlessly, while others only get there with massive support.

The beginning can often be compared to an odyssey through false diagnoses, followed by the search for the right diagnosis and therapy - rare diseases are apparently not much dealt with in medical training and years of practice. It is not uncommon for patients to be dismissed as being psychologically deviant and left alone. The consequences can be lower self-esteem and/or social withdrawal with acceptance of the health and psychosocial consequences, such as physical pain or social exclusion. This is often aggravated by too little knowledge amongst the public or the responsible contact persons at the beginning of such a path in life e.g. information on established compensation rights for disadvantages which can then support the patient in the development of his or her professional career. If the disease is visible, this adds more stress: being stared at or being insulted and a halo effect, e.g. being perceived as being less able. If the disease is not visible, some of these difficulties are lessened, but other aspects come into focus, such as excessive expectations, a failure to recognize the patient's limits, or an inclination to dismiss him or her as a simulator. This is where the above-mentioned loops start up, which can be repeated in every phase of life, in every new social environment.



Some of the active members

What is the name of what I have? An important point! To finally be able to name the illness helps in accepting it. This is followed by the next challenge. There is no uniform, standardised therapy! There are different strategies and medication for each disease form and it always means weighing up the efficacy against the side effects. Patients and relatives have to get used to choosing from alternative therapy approaches and waiting for alleviative or healing therapies and medications. Often patients must be prepared to take risks in order to regain their quality of life. And they always have to make this decision for themselves or their child without knowing in advance where the journey will take them. Further worries, many unanswered questions and great uncertainty arise from the structures in medical care: a scarcity of specialist appointments, hardly any emergency clinics, no local medical care and thus lengthy and costly journeys, incomprehensible technical language, poor medical referrals and insufficient aftercare management. The dependence that a rare chronic disease brings with it is an enormous stress. And fear of the future with regard to one's own capabilities amplifies only this stress.

▮ 'No matter how hard I try, it's not enough anyway.' (T.B.)

The uncertainties surrounding the illness and one's own perspectives together with the huge strain of dealing with everyday life sometimes lead to anxiety and resignation, lower self-esteem, a refusal to perform at school and at work, withdrawal from medical treatment, anger, feelings of inferiority, depression, drug abuse and phases of isolation from friends or family. In addition to feelings of shame and shyness, there are also worries and fears that one lacks the strength to live with and endure the disease; worries about the future, embolisms, pain, operations, decisions regarding doctors or therapies, about becoming a partner or parent. Relatives - parents, siblings, family, partners and friends are emotionally connected and feel responsible. They are also challenged as the disease impinges on many areas of their shared lives. The disease can also lead to restrictions in one's choice of profession and career opportunities, loss of income with lower pension rights, longer periods of inability to work and increased medical costs. The different aspects show that the disease is present and it is a lifelong issue. And that is exactly why a zest for life and light-heartedness should definitely have their place!

▮ 'I now believe that you can deal with the disease in a way that you can say: Yes, I have a congenital vascular disease. But that is only a PART of me. The intensity of the disease sometimes depends on how much space we allow it.' (L.B.)

We know: We are not all equally strong. But there are many positive examples of how people with a congenital vascular

malformation live their lives with self-confidence and love. And there are many committed and emphatic doctors, who perceive the whole person.

▮ 'Nobody has to take this path alone.' (M.B.)

It is much easier with good companions or in a group. Experiences and life plans as well as helpful tips are passed on. Individual, personal, positive experiences with the illness help to clarify life's priorities and uncertainty and worries can lead to a growth of courage and self-esteem.

▮ 'Finally, a few things that help me to deal with my illness: I now talk openly about all facets of my illness - this is liberating! Becoming aware of your own history - that can help to put your thoughts in order! Involving friends and family, addressing uncertainties and seeking help - helps to feel good! Taking appointments with doctors, getting examined, and being treated – means taking care of yourself! When operations and procedures are over, turn to the other things in life! Pass on your own experiences and exchange with others!' (L.B.)

But there are also many people who find it difficult to be open about their illness. Today's society sets very high performance standards making it very difficult, especially for young people, to admit to their limitations for fear of underachieving, society likely to, expel those who fail to fulfill expectations. This of course also bears consequences on the life of those involved. In the end, each individual dealing with the illness is involved in a constant struggle to find a compromise between its necessary acceptance and the desire for quality of life. This is sometimes incomprehensible for outsiders.

▮ 'For the future, I hope that the topic of "rare diseases" will be borne further and further into politics, that we will not have to fight for every prescription for compression products or for important lymphatic drainage, but that we too "belong" with a rare disease, and we will continue to have such great doctors who deal with these malformations, sometimes beyond what is expected of them. Simply put, I hope that we can LIVE with our "other plan".' (René Strobach, 1st Chairman of the Federal Association of Congenital Vascular Malformations)

The OVAMA project

Max M. Lokhorst, MD (PhD candidate), member of the Dutch national network of VASCA

The field of vascular malformations has been hampered by heterogeneity in outcome measures, lack of evidence-based treatments and a lack of evaluation of treatment effects from the patient’s perspective. This while treatment of vascular malformations is generally targeted at improving the patient’s condition-specific symptoms and their often severely impacted quality of life.

The mission of the OVAMA (Outcome measures for Vascular Malformations) project is to uniform outcome reporting in clinical research on peripheral vascular malformations.

Without harmonisation of outcome measures, treatments cannot be properly compared. This hampers the development of evidence-based treatment guidelines, which are urgently needed for these challenging congenital conditions.

What to measure?

Outcome domains

To evaluate treatment efficacy, the first step was to determine what to measure. We have developed a core domain set (CDS) for evaluating treatment outcomes in peripheral vascular mal-

formations (Figure below). A CDS is a minimum set of outcome domains that should be measured when evaluating treatment outcome for a certain condition. This international consensus project, including 167 physician and 134 patient/parent contributors, consisted of a three-round e-Delphi study, an online consensus meeting and a face-to-face consensus meeting.




Photo: M. M. Lokhorst

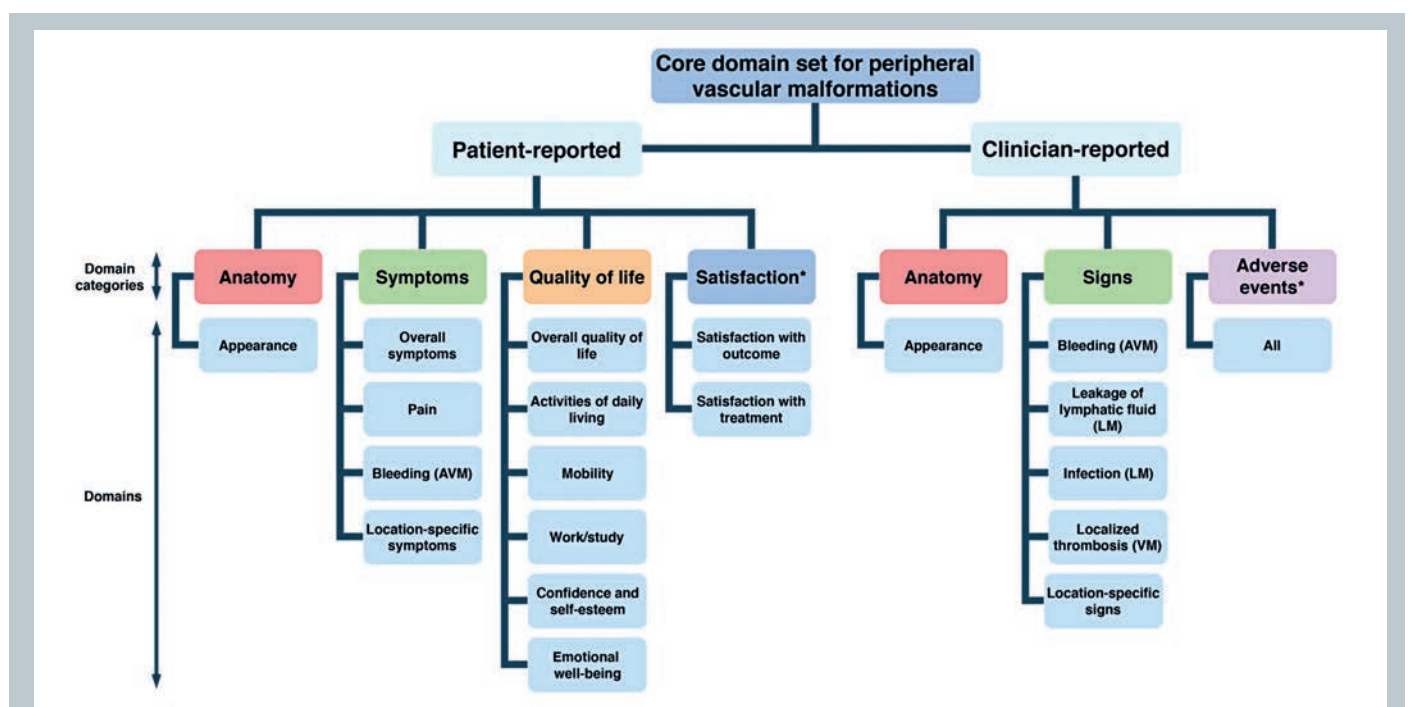
Core domain set

The figure below shows the final core domain set for peripheral vascular malformations*.

How to measure?

Outcome measurement instruments

The next step towards uniform outcome reporting was determining how to measure the core domains, i.e. developing a core outcome measurement set (COMS). This project, involved an appraisal and the validation of existing instruments



Core domain set for peripheral vascular malformations. AVM = only for arteriovenous malformations, LM = only for lymphatic malformations, VM = only for venous malformations, *only relevant at follow-up.

Photo: Lokhorst MM, Horbach SER, van der Horst C et al. Finalizing the international core domain set for peripheral vascular malformations: the OVAMA project. The British Journal of Dermatology 2019.

and development of a new disease-specific instrument: the OVAMA questionnaire.

Patient-reported outcome measures

Existing instruments

Four patient-reported core domain categories were determined: **1. Anatomy (appearance), 2. Symptoms, 3. Quality of life and 4. Satisfaction.**

A systematic review on outcome measurement instruments in vascular malformations yielded no validated patient-reported outcome measures (PROMs) for all core domain categories. To correctly evaluate treatment outcome, outcome measurement instruments are needed that are able to detect changes in the outcomes before and after treatment, which means that the measurement instruments must be responsive to change (longitudinal validation). It is generally advised to measure 'universal' domains (such as the core domains falling under 'quality of life') with generic instruments. In following studies, we therefore assessed if 4 widely used generic PROMs were responsive to changes in quality of life in both adults (SF-36, Skindex-29) and children (PedsQL, CDLQI) with vascular malformations. Unfortunately, all 4 PROMs seemed not responsive to changes in quality of life. No PROMs exist for measuring vascular malformation appearance, symptoms, and satisfaction.

PROMIS and the OVAMA questionnaire

For the more universal domains falling under quality of life, we are currently (longitudinally) validating the generic PROMIS (Patient-Reported Outcomes Measurement Information System) scales. This includes the scales 'pain-interference', 'depression', 'anxiety', 'ability to participate in social roles and activities', 'mobility' and 'upper extremity functioning'. These scales are already thoroughly tested in large populations, available for both adults and children and in multiple languages, and can be administered as short forms or computer adaptive tests. For the more disease-specific domains, we have developed the 'OVAMA questionnaire'. This comprises of the following scales: 'general symptoms', 'appearance', 'head and neck symptoms' and 'satisfaction with outcomes and treatment strategy'. The head and neck symptoms scale is only intended for patients in which the head and neck region is affected. In prospective studies, the satisfaction scale needs only to be completed at follow-up.

Clinician-reported outcome measures

Three clinician-reported core outcome domains were determined: **1. anatomy (appearance), 2. signs and 3. adverse events.**

Existing instruments

A systematic review on outcome measurement instruments in vascular malformations yielded no validated clinician-reported outcome measures for all core domain categories. A clinician-reported appearance scale will be developed, as well as concise checklists for clinical signs and adverse events.

Relevance

With the development of the core outcome set and the OVAMA questionnaire, problems that matter most to patients with vascular malformations can be evaluated.

The OVAMA project will allow us to tackle the current heterogeneity in outcome measures and thereby allow for comparison of treatments. Treatments can then be tailored more to the individual patient, which is essential in this heterogeneous patient group. Additionally, the OVAMA questionnaire enables definition of clinically distinct groups, which allows for classification on disease severity based on the severity of symptoms and appearance problems. This is even more pressing with the emerging gene-targeted therapies, which will predominantly play a role in more severe cases, for which a proper definition is currently lacking. The many applications of the OVAMA project may significantly improve research, and ultimately, the care for patients with vascular malformations.

* The full article can be found here:

- www.onlinelibrary.wiley.com/doi/full/10.1111/bjd.18043

OVAMA questionnaire




- www.ovama.org/ovama-questionnaire/

PROMIS

- www.healthmeasures.net/explore-measurement-systems/promis

Generated with www.qrcode-monkey.com

Please scan

Full article	PROMIS	OVAMA
		

Max M. Lokhorst, MD (PhD candidate)
 Department of Plastic, Reconstructive and Hand Surgery, Amsterdam UMC, University of Amsterdam
m.m.lokhorst@amsterdamumc.nl

TESTIMONIAL

Living with narrow escapes – a personal story of joyful ups and traumatic downs

Aaike, Hajni & Max (LGD Alliance Europe)

It was April 2012. Around noon on Friday 13th our Bo was born. To us, 13 immediately became our lucky number. After a year and a half without any surprises Bo turned out to be special, as we called him rather than having a disease. Fluid was building up behind his lungs. After a short admission to the ICU and a thorough study of the possible diagnoses, he was diagnosed with General Lymphatic Anomaly or Central Conductive Lymphatic Anomaly, although these exact names didn't exist yet by then.

Bo was lucky and benefited from new research from the United States on Sirolimus that had been tested on 6 children and gave good results. We felt that Bo often had the good fortune that doctors had just developed or discovered something new to treat him with. After 6 weeks of medication and drainage of the lymph fluid Bo's condition improved in such a way that he could continue his life without a drain.

But in the year that followed, we got to deal with all kinds of side effects of the disorder, such as pain and physical obstacles.

The complications that hit Bo were special. Once Bo was not allowed to eat anything for a period of 6 weeks because his intestines were completely upset from medication. His mental resilience to accept what had to be done by the doctors and then move on was amazing.

He was very smart too. The teacher called him the class calculator. He was also very quick to read. When Bo was just six years old and had to spend 10 days in the ICU, he quickly learned to 'chat' with us via a letter card. He was chatting all the time, although he was all connected with tubes via his nose and mouth. On several occasions Bo also surprised us physi-

cally as well. After four months in bed, he couldn't walk anymore. But a few months later he managed to walk with us in a winter holiday in Switzerland.

In life, children are usually carefree. But Bo unfortunately had a lot of pain to deal with, sometimes bearable, and sometimes not so much. We as a family, together with doctors tried to reduce that and provide distractions.

Sometimes Bo had good moments, days, and even weeks without pain. Those moments we always tried to use the vibe and energy to be creative and expressive.

Then we looked ahead and made plans for happy moments and enjoy the holidays.

But Bo also knew very well what his limits were. He was always a little worried about being able to handle something. Physically, but also mentally. He didn't take many chances. At the same time, he was always open to suggestions, a reward system, new ideas or an experiment with which he could better handle his life with limitations. He was very rational about it.

As parents we experienced traumas and shocks as well, which we did not solve on our own. Several times we got counselling or a training to cope with stress or post-traumatic stress syndrome. Don't think that you will solve it by yourself because you are stronger than others. We have been there...



Those weeks and months we spend in hospitals, we arranged our support (food and care for our second child) via CareCalendar.org. Friends and family could pick items and time slots to help us out. It gave us the chance to be there for Bo and others to be there for us as parents.

Especially dramatic was the tragedy that struck in 2020. During the corona crisis, we adhered to hygiene regulations very strictly. We hardly went out as a family and didn't meet anyone. We celebrated his birthday safely and cosily with Zoom and balcony scenes. At the end of April, Bo suddenly developed a fever and shortness of breath. It didn't have anything to do with Corona. Pneumococcal infection turned into pneumonia. Rare, given that we're vaccinated for that. Even rarer was the fact that the pneumococcal bacteria had also infected blood vessels in his head, causing the vessel walls to swell with oxygen deficiency in the brain as a consequence. It all happened in a matter of days. Bo slipped into a coma. Three days later, just when we thought there was nothing more to be done, he regained consciousness. We were over the moon. But it didn't make it any easier, for Bo was still completely paralysed. He could hear us, but we communicated with him through eye movements. We waited another week to see if his body had a rare recovery in store. But this time the escape was one too many for Bo. But as always, Bo was patiently waiting to get better. Bo felt pretty at home in the Emma Children's Hospital in Amsterdam.

Despite the gloomy news, we as a family have managed to show Bo that he not only has a special body, but also that he was always extraordinarily brave and patient in difficult times. He earned a big compliment for the way he led his not-so-carefree life.

Bo was awarded a certificate in the ICU by his hero, astronaut André Kuipers, for bravest and toughest paediatric patient 2020. Bo enjoyed the story of André's space trip. He also gave Bo and his younger brother Max the honorary title 'Co-astronaut of spaceship Earth'.

That day we could give Bo positivity and admiration for his perseverance. He received dozens of personal congratulations from personal visits and via video messages over the Internet. He clearly felt the pride that friends, classmates and family all felt for him.

Photo: Remko van Diggelelen

Eventually, Bo passed away peacefully in his sleep. We, the doctors and other adults around us knew that was inevitable. Bo's schoolmates didn't fully understand the severity until it was too late. Two days after he died, the schools reopened in the Netherlands. Luckily his schoolmates could process the loss of their friend together.

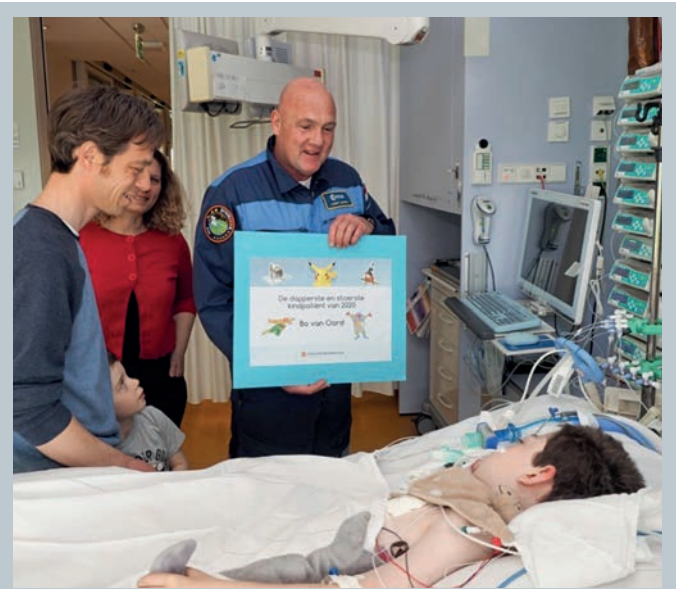Facing such a dramatic farewell is traumatising. We chose to face it by organising a celebration for Bo at the ICU. Thanks to the doctors of the Emma Children's Hospital in Amsterdam we could organise it the way we wanted. It is a very valuable memory, a positive moment between all the sorrow.

We visited the class a month later to show the kids more about the special body of Bo, why he had passed away and talk about memories they had of Bo. This was a very emotional session for us, but it turned into another valuable memory.

Almost one year later, we still feel ups and downs and we still have counselling on a regular basis. We miss our Bo as he changed who we are. His passing left a hole in our team. The remaining team is still regrouping but it's making new memories again as well.

“ A lot is possible in life, you have dreams for a reason.

André Kuipers



After diagnosis

You have a child with a (rare) disease and you do not yet have a (correct) medical diagnosis. But then, you finally get the medical diagnosis. And then... What rages through you as parents? 'What does the future look like for our child and us? What can or can't our child do later? What is the life expectancy of our child? What is the impact of this on our family? Will our child be able to live independently and have a nice life?' And so on.

After the initial shock

'What does this diagnosis mean? What can I expect? Is it okay to feel the way I feel? How do I deal with it?'

After hearing the diagnosis of your child, you will have a lot of questions and / or you will go looking for help, understanding and support. That is very normal. You, as a parent, are not alone. If you have just heard that your child has a disability or chronic illness, you embark on a long, often emotional, journey. You enter a completely new world, full of doctors, therapists and rules that you have probably never heard of. To ensure that you find your way in this, it is good to find out as much as possible about the condition that makes your child - and therefore your life - special. Some parents don't remember anything about the first time after the diagnosis. Others describe it as 'a black bag' that was pulled over their head or a knife that was inserted into the heart.

But there are also parents who experience relief because, after years of diagnostic searching, they finally receive an answer to their question. Some parents do not experience any of the above. They are not sad, their world is not collapsing, but they have received confirmation of something they have had an (indefinable) feeling about for a long time. In short, how you experience hearing the diagnosis is very personal. Fortunately, there are plenty of resources that can help you get through this period properly, should you need it. The realisation that you are not the first and certainly not the only one to experience this, for example, is hopefully a consolation. That is why we describe how parents can react differently and give practical tips and advice, so you don't have to reinvent the wheel.

Every child is different and every parent is different, so what you read here may not exactly refer to your situation. Nevertheless, we hope that this article answers questions that you may have and that it offers enough tools to help you lead a normal, happy life with your child. Though it may be hard to imagine, there will come a time when the first thing you notice when you look at your child, is the amazing and unique individual, and not the disease or disability.

Johannes Verheijden (CMT-C-OVM)

Rollercoaster of emotions

So many feelings ... You may feel enormously protective and loving towards your child but you are extremely angry because your child has this condition or chronic illness. You may continue as if nothing is wrong, or act as a 'stand-by' zombie. All these feelings are very normal.

It could take a month to give your child's disability or chronic illness a place in your life, but also years.

You will have good days and bad days, but most will be normal, just like in any other family. It is very normal to have feelings of:

1. Denial.
2. Confusion.
3. Powerlessness.
4. Disappointment.
5. Rejection.

How do you deal with your emotions?

Everyone has their own way of handling violent or emotional situations. We call that 'coping' strategies. You will find that some ways of handling things work better than others. If you notice that a problem or worry is diminishing instead of getting worse, you know that something works.

1. Talk.
2. Cry.
3. Read.
4. Pray.
5. Contact with other parents.

How do you tell your environment?

When you hear the diagnosis, first of all you will feel sad about it. But the people who love you usually feel the same pain, fear, confusion and disappointment. They worry even more than you sometimes. Therefore it is not always easy to inform family and friends and to take them with you in the process. Your own parents, brother, sister or close friends can disappoint you. For example, because they are afraid to pick up or babysit your child. That's a shame, but remember that this happens in all families. Part of that disappointment is also in the grieving process of these family members, such as the difficult denial and anger. The best thing you can do is clearly tell what is wrong with your child and how you want to deal with it yourself. For

they say something strange because they're nervous. Although you cannot determine how people react, you can determine how you deal with looks or questions. Try not to worry about people who are unable to respond in ways you might prefer. As a parent of your child there are better ways to use your energy.

You don't have to explain anything

No matter how you decide to respond in a certain moment, remember that nobody wants to teach the rest of the world. The condition or illness is a part of your child, just like the color of their eyes or hair. However, it says nothing about who your child is.

Impact on family

'You are never alone when you have a disability or illness', people sometimes say. Your child's diagnosis also has an impact on everyone in the house.

When it comes to your first child, you will need to find a new balance as husband and wife. If you already have children, the whole family will have to get used to the new situation. Fortunately, most families quickly find a nice balance again.

You want to help your child develop fully. You may give 100% of yourself for that, but if you focus all your energy on one person in the family, nothing else remains. Therefore, make sure that you create a harmonious home in which everyone receives the love, attention and support that he or she needs, including you!

How do you deal with it together?

If you react differently to the diagnosis than your partner does, it can cause tension. If one of you reacts more emotionally and the other prefers to be more practical, give each other plenty of room and keep telling each other how you feel and whether you want to talk about it. It is also very important to accept each other's way of processing the diagnosis. Don't get angry if your partner just cries or if he or she just can't stop 'Googling'. Decide together how best to care for your child and family. Make sure that you are clear about your expectations of each other, and keep doing fun things together, even without children. That way you will become a strong team.

How do you explain it to your other children?

When you come home with your new child (or after you receive your child's diagnosis), the other children may sense from

you that there is something wrong and may become a little alarmed to hear that their brother/sister has a disability or is unwell. How do you explain this to them? Of course, every parent must find their own way to do this, however, here are a few tips that may be of help.

1. **Be honest.**
2. **Be clear.**
3. **Toddlers.**
4. **School-aged children.**
5. **Siblings.**
6. **You set the tone.**

What can you do yourself?

For the most part, life continues 'as usual' after hearing the diagnosis. Your child needs attention, love and care, perhaps more care than other children of their age. What is the best way to provide this care? You will learn this over the coming months and years with the help of counsellors, doctors and/or therapists.

Your child is more than the condition

The best thing to do is to treat your child in the most normal way possible. Your child can be sweet, mischievous, happy and curious, but sometimes angry, grumpy and rebellious. In short, they have the same range of emotions other children their age has. Be careful not to only see your child's medical condition, your child is so much more than that. They are unique little people with their very own personality, gifts and interests.



Photo: Lex van der Heijden

Playing is learning

Interact with your child as normally as possible. Challenge them to move, play and explore without focussing too much on their medical conditions. Play with your child as you would with any other. Small daily activities, such as brushing your teeth, washing the dishes, cooking or walking the dog can also be fun learning moments. How do you deal with doctors and therapists?

There will be times when you feel that your child is being surrounded by different professionals all wanting to help and it can feel overwhelming at the beginning. There may be times when you feel that you are not in control of the situation but remember that this is not the case. It is important that you feel happy with whatever is happening around your child, make sure that you have the information that you need to take care of your child at home.

Sometimes communication between professionals themselves can be unclear, so it is vitally important when communicating with a large group that everyone is clear about their own responsibilities and communicate clearly how to support you and your child. It might be an idea to keep a communication logbook. Remember you also have the right to access your child's files at many hospitals.

Keep control yourself.

1. Stay informed.
2. Ask for clear communication.
3. Educate yourself.
4. Let doctors and therapists help you.

Don't forget to raise your child

As a parent of a child with a disorder or chronic illness, you probably tend to do too much for your child and demand too little, while you should really do everything you can to make your child as independent as possible. From an early age, try not to protect your child more than is necessary. Children should be allowed to have their own experiences so that they can learn from their mistakes.

Guide for parents after the diagnosis

cmtc ovm
www.cmtc.nl

You can find this and other brochures on the website of CMTC-OVM.

Photo: Lex van der Heijden

Generated with www.qrcode-monkey.com

Tips to take action yourself

1. Organise yourself.
2. Organise your house.
3. Set realistic goals.
4. Write down your questions.
5. Make a booklet.

Editor's note:

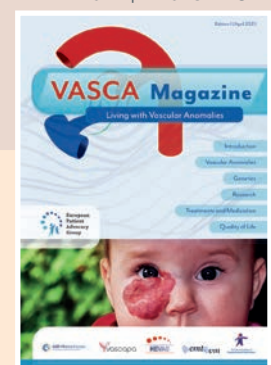We hope the first issue of VASCA Magazine has brought you new and valuable information about:

- /// the work of VASCERN and the VASCA-Working Group,
- /// the work of Patient Organisations, how they can support patients and their relatives, help advance research,
- /// about Vascular Anomalies and their classification, genetics, treatment, research and possible future medications.

We believe that the VASCA Magazine can become a useful tool for doctors, medical personnel, patients and carers. Hence our willingness to make it an annual magazine. If you are willing to help, please contact us through any of the Patient Organisations (see page 2) and/or we invite you to make a donation (see page 19). Thank you!

Best regards from the editorial team

Ed. 1 | March 2021



Glossary

Alpelisib (BYL719)

see 'drugs'

Arteriovenous malformation (AVM)

An AVM is a vascular malformation with abnormal tangle of blood vessels connecting arteries and veins, which disrupts normal blood flow and oxygen circulation.

Bleomycin

see 'drugs'

Camouflage technique

The technique is used to conceal redness etc. by means of a strong make-up.

Capillary malformation

A capillary malformation - sometimes called a 'port-wine stain' - is a kind of birthmark that looks like a flat, red-pink stain on your child's skin. Capillary malformations are vascular malformations caused by dilated capillaries (small blood vessels) in the skin that enlarge and darken as a child grows older.

Central conducting lymphatic anomaly (CCLA)

Central conducting lymphatic anomaly (CCLA) is one of a spectrum of complex lymphatic anomalies with multiple overlapping symptoms. Enlargement of lymphatic channels (lymphangiectasia), dysmotility, or distal obstruction results in inadequate clearing of lymph with resultant stasis and reflux.

Cerebral arteriovenous malformations (Brain AVM)

An arteriovenous malformation (AVM) is a tangle of abnormal blood vessels connecting arteries and veins in the brain.

Cerebral cavernous malformations (CCM)

Cerebral cavernous malformations (CCMs), also called cavernous angioma, cavernous hemangioma or cavernoma, are vascular lesions comprised of clusters of tightly packed, abnormally thin-walled small blood vessels (capillaries) that displace normal neurological tissue in the brain or spinal cord. The abnormal tissue causes a slowing of blood flow through the cavities, or 'caverns'.

Cutaneous infantile haemangiomas

See 'haemangioma'

Cutis Marmorata Telangiectatica Congenita (CMTC)

Cutis marmorata telangiectatica congenita (CMTC) is a congenital localised or generalised vascular anomaly and is characterised by permanently bluish or deep purple marbled skin, spider nevus telangiectasia (spider veins), phlebectasia (Dilatation or ectasia of a vein) and occasionally ulceration and atrophy (loss) of the affected skin.

DNA

DNA, short for deoxyribonucleic acid, is the molecule that contains the genetic code. DNA is in each cell and tells cells what proteins to make. Mostly, these proteins are enzymes.

Drugs

There are no original drugs for the treatment of vascular anomalies. The drugs that have been used for some time or recently for vascular malformations are mainly from cancer treatment and are partly still in the first stage of research. Others, such as sirolimus, have been in use for years (see article 'Future Op-

tions in the Treatment of Vascular Malformations' on page 51).

Embolisation

see 'sclerotherapy'

Epidemiological surveillance

Epidemiological surveillance is the 'ongoing systematic collection, analysis, and interpretation of health data that are essential to the planning, implementation, and evaluation of public health practice'.

EURORDIS

EURORDIS is a non-governmental patient-driven alliance of patient organisations representing 956 rare disease patient organisations in 73 countries.

Facial Infiltrating Lipomatosis (FIL)

Facial infiltrating lipomatosis (FIL), also referred to as congenital infiltrating lipomatosis of the face or facial infused lipomatosis, is an ultra-rare craniofacial overgrowth condition caused by a genetic mutation of the PIK3CA gene (see 'PROS').

General lymphatic anomaly (GLA)

Generalised lymphatic anomaly (GLA) - previously known as lymphangiomatosis - is a rare, congenital and progressive disorder of lymphatic channels which can affect different organs including the bones and the intestines.

Congenital

Present at birth.

Gorham's Disease/Gorham Stout Disease (GSD)

Gorham-Stout disease (GSD), which is also known as vanishing bone disease, disappearing bone disease, massive osteolysis, and more than a half-dozen other terms in the medical literature, is a rare bone disorder characterized by progressive bone loss (osteolysis) and the overgrowth (proliferation) of lymphatic vessels.

Haemangioma (or Hemangioma)

Infantile haemangiomas are very common benign tumours in the first months of life. In VASCA-WG we only focus on the rare and complicated forms which require treatment, due to location, size or its intrinsic characteristics.

Inhibitor

An inhibitor slows down or prevents a chemical or biochemical reaction.

Intracranial

Intracranial means 'inside the skull'. The term is used to describe structures or processes that lie within the cranial cavity, i.e. in the hollow space formed by the bones of the skull.

Intraspinal

Intraspinal means 'inside the spinal canal'.

ISSVA

The International Society for the Study of Vascular Anomalies (ISSVA) is the formalisation of prior biennial international workshops, which were started in 1976, of specialists interested in the diagnosis, management and investigation of these disorders.

ISSVA classification

ISSVA classification for vascular anomalies (approved at the 20th ISSVA Workshop, Melbourne, April 2014, last revision

May 2018) is a majority accepted division of vascular anomalies into vascular tumours and malformations and into subtypes of vascular malformations with the aim of a unified understanding because of the need for separate therapeutic measures.

Kaposiform lymphangiomatosis (KLA)

Kaposiform lymphangiomatosis (KLA) is an extremely rare condition in which the vessels that carry lymphatic fluid throughout the body expand and interconnect. These abnormal lymphatic vessels invade and cause damage to surrounding tissue, bones and organs.

Klippel-Trénaunay syndrome (KTS)

Klippel-Trénaunay syndrome formerly Klippel-Trénaunay-Weber syndrome and sometimes angioosteohypertrophy syndrome and hemangiectatic hypertrophy, is a rare congenital medical condition in which blood vessels and/or lymph vessels fail to form properly. The three main features are nevus flammeus (port-wine stain), venous and lymphatic malformations, and soft-tissue hypertrophy of the affected limb. It is similar to, though distinctly separate from, the less common Parkes Weber syndrome.

Lymphatic anomaly (malformation)

A lymphatic malformation is a clump of abnormal lymph vessels that form a growing, disorganized, spongy cluster of cysts. They appear as masses (unusual growths), but they are benign (not cancerous).

Microcystic lymphatic malformation

It is a rare common cystic lymphatic malformation characterized by a benign cystic lesion composed of dilated lymphatic channels. Microcystic lesions consist of cysts smaller than 1 cm in diameter.

Miransertib

see 'drugs'

OK-432

see 'Picibanil'

OVAMA project

The mission of the OVAMA (Outcome measures for Vascular MAIformations) project is to uniform outcome reporting in clinical research on peripheral vascular malformations.

Peripheral vascular malformation (PVMs)

Peripheral vascular malformations compass a wide spectrum of lesions that can present as an incidental finding or produce potentially life- or limb-threatening complications. PVMs are relatively common within the extremities and usually confined to the subcutaneous tissues and muscles.

PROS

PIK3CA-related overgrowth spectrum (PROS) is a group of rare genetic disorders with asymmetric overgrowth caused by somatic mosaic mutations in PI3K-AKT-mTOR pathway (see articles about genetics and medication) that encompass a heterogeneous group of rare disorder that are associated with the appearance of overgrowth. CLOVES syndrome and Klippel-Trénaunay syndrome are PROS disease. Proteus syndrome is an overgrowth syndrome caused by a somatic activating mutation in AKT1.

PIK3CA

see 'PROS'

Picibanil (OK-432)

Picibanil is a sclerosant and immunostimulant and used for the treatment of lymphatic malformations. OK-432 is injected directly into the tumour or lymphangioma (intralesional). It produces an immune reaction with local inflammation at the injection site. Afterwards, a shrinkage process of the tissue leads to sclerosis and thus to the regression of the cystic structures.

Port wine stain

See 'capillary malformation'

Propranolol

see 'drugs'

PTEN syndrome

The PTEN hamartoma tumor syndrome (PHTS) summarizes several heterogeneous disease patterns (syndromes) caused by heterozygous germline mutations of the tumor suppressor gene PTEN.

Sclerotherapy

Sclerotherapy and embolisation are terms that are often used interchangeably. By both, it is meant that the deviant vessels of the vascular malformation are closed off. There are two ways of doing this:

1. by inserting something that blocks the blood vessel (embolisation) - or -
2. by damaging the wall of the blood vessel in such a way that the blood vessel becomes blocked (sclerosing).

Sirolimus

see 'drugs'

Syndroms

Some vascular tumors and malformations develop in isolation, whereas others develop within the phenotype of a syndrome (combination of different disorders, changes or diagnostic findings).

Talselisib

see 'drugs'

Vascular anomaly

Vascular anomalies are pathologies that affect the formation of the blood or lymphatic vessels.

Generally, vascular anomalies are divided into vascular tumours and vascular malformations. The latter are defined regarding the diseased vessel section. There is a differentiation between simple vascular malformations (capillary, lymphatic, venous and arteriovenous) and combined lesions (e.g. capillary-venous). Vascular malformations can appear in combination with other anomalies as a syndrome (e.g. Klippel-Trenaunay syndrome, CLOVES syndrome, Parkes-Weber syndrome).

Vascular malformation

Vascular malformations are a type of vascular anomalies (see 'vascular anomalies').

Vascular tumour

Vascular tumours are a type of vascular anomalies (see 'vascular anomalies').

Venous malformation (VM)

Venous malformations are a type of vascular malformation that results from veins that have developed abnormally, which stretch or enlarge over time.

VASCA-WG Healthcare Providers (HCP) Full members

Prof. Miikka VIKKULA	Clinical Geneticist	Cliniques Universitaires Saint-Luc BELGIUM ○ www.saintluc.be
Prof. Laurence M. BOON	Plastic and Reconstructive Surgeon	
Prof. Leo SCHULTZE KOOL	Interventional Radiologist	Radboud University Medical Center NETHERLANDS ○ www.radboudumc.nl
Dr. Carine VAN DER VLEUTEN	Dermatologist	
Prof. Päivi SALMINEN	Pediatric Surgeon	Helsinki University Hospital FINLAND ○ www.hus.fi/en
Adjunct Prof. Kristiina KYRKLUND	Pediatric Surgeon	
Dr. Friedrich KAPP	Pediatric Hematologist/Oncologist	Medical Center - University of Freiburg GERMANY ○ www.uniklinik-freiburg.de/en
Prof. Jochen RÖSSLER	Pediatric Hematologist/Oncologist	
Dr. Veronika DVORAKOVA	Consultant Dermatologist	Children's Health Ireland IRELAND ○ www.olchc.ie
Prof. Alan IRVINE	Professor of Dermatology	
Dr. Andrea DIOCIAIUTI	Dermatologist	Bambino Gesù Children's Hospital ITALY ○ www.ospedalebambinogesu.it
Dr. Maya EL HACHEM	Dermatologist	
Dr. Nader GHAFARPOUR	Pediatric Surgeon	Karolinska University Hospital SWEDEN ○ www.karolinska.se/en
Prof. Filip FARNEBO	Plastic Surgeon	

Affiliated Partner

Dr. Paolo GASPARELLA	Pediatric Surgeon	University Hospital Graz AUSTRIA ○ www.klinikum-graz.at
Prof. Emir HAXHIJA	Pediatric Surgeon	

VASCERN Coordination

Assistance Publique-Hôpitaux de Paris, Hôpital Bichat-Claude Bernard
Centre de Référence (CRMR) Syndrome de Marfan et apparentés
46 rue Henri Huchard – 75018 PARIS, France

Prof. Guillaume JONDEAU	VASCERN Coordinator - Cardiologist
Marine HURARD	VASCERN Project Manager
Natasha BARR	VASCERN Project Officer
Karen DAOUD	VASCERN Project Officer
Ibrahim DONMEZ	VASCERN IT Helpdesk & End User Support Specialist

VASCA Working Group
built upon Multidisciplinary Centres of Excellence for Vas-
cular Anomalies
○ vascern.eu/expertise/rare-diseases-wgs/vasca-wg/
#1461009962709-540360ce-6a2e

Please scan



List of Authors

Prof. Leo J. Schultze Kool, MD, PhD, EBIR

Department of medical imaging
Radboud University Medical Center
P.O. Box 9101, 6500 HB Nijmegen (Netherlands)
www.radboudumc.nl
Leo.Schultzekool@radboudumc.nl

Priv. Doz. Dr. med. Philipp Dammann

Neurosurgical Clinic
Essen University Hospital
Hufelandstrasse 55 | 45147 Essen (Germany)
www.uk-essen.de/neurochirurgie/
philipp.dammann@uk-essen.de

Dr. med. Friedrich Kapp

Division of Pediatric Hematology and Oncology
Department of Pediatrics and Adolescent Medicine
Medical Center - University of Freiburg
Mathildenstraße 1 | 79106 Freiburg (Germany)
www.uniklinik-freiburg.de
friedrich.kapp@uniklinik-freiburg.de

Prof. Guillaume Jondeau, MD, PhD

VASCERN Coordinator
Center of Reference (CRMR) for Marfan Syndrome
and related Disorders
AP-HP, Hôpital Bichat-CLaude Bernard
46 Rue Henri Huchard, 75018 Paris (France)
www.vascern.eu
contact@vascern.eu

Nader Ghaffarpour, MD, PhD

Department of Reconstructive Plastic- and
Craniofacial Surgery
Vascular Anomaly Center
Karolinska University Hospital Stockholm (Sweden)
www.karolinska.se
nader.ghaffarpour@sll.se

Prof. Laurence M. Boon, MD, PhD

Dermatology and Plastic Surgery
Cliniques universitaires Saint-Luc (UCLouvain)
Avenue Hippocrate 10
Woluwe-Saint-Lambert, 1200 Brussels (Belgium)
www.saintluc.be
laurence.boon@uclouvain.be

D. Maroeska W.M. te Loo, MD, PhD

Pediatric Hematologist and Clinical Pharmacologist
University Hospital Nijmegen, Radboudumc
Department of Pediatrics
P.O. Box 9101, 6500 HB Nijmegen (Netherlands)
www.radboudumc.nl
Maroeska.teLoo@radboudumc.nl

Willemijn M. Klein, MD, PhD

Amalia Children's Hospital
Pediatric radiologist
Radboud University Medical Center
P.O. Box 9101, 6500 HB Nijmegen (Netherlands)
www.radboudumc.nl
Willemijn.klein@radboudumc.nl

Prof. Miikka Vikkula, MD, PhD

Laboratory of Human Genetics
de Duve Institute
Avenue Hippocrate 74,
Woluwe-Saint-Lambert, 1200 Brussels (Belgium)
www.deduveinstitute.be
miikka.vikkula@uclouvain.be

Andrea Diociaiuti, MD, PhD

UOC Dermatology
Bambino Gesù Children's Hospital
Piazza di Sant'Onofrio, 4, 00165 Rome RM (Italy)
www.ospedalebambinogesu.it
andrea.diociaiuti@opbg.net

Max M. Lokhorst, MD (PhD candidate)

Department of Plastic, Reconstructive and Hand Surgery
Amsterdam UMC, University of Amsterdam
Location AMC, G4-254 | Meibergdreef 9, 1105 AZ,
Amsterdam (Netherlands)
https://vumc.nl
m.m.lokhorst@amsterdamumc.nl

Mina Todorovic, DVM, MSc

Project manager
de Duve Institute
Avenue Hippocrate 74,
Woluwe-Saint-Lambert, 1200 Brussels (Belgium)
www.vacure.eu
mina.todorovic@uclouvain.be

This publication has been financially supported by the European Reference Network
on Rare Multisystemic Vascular Diseases (VASCERN)

Project ID: 769036, which is partly co-funded by the European Union within the framework of the Third Health
Programme ERN-2016 - Framework Partnership Agreement 2017-2021.



EUROPEAN UNION



Photo: AdobeStock_73868450

www.vascern.eu



European Reference Network

VASCERN

Gathering the best expertise in Europe to provide accessible cross-border healthcare to patients with rare vascular diseases



European Patient Advocacy Group

VASCA

